



**stryker**<sup>®</sup>

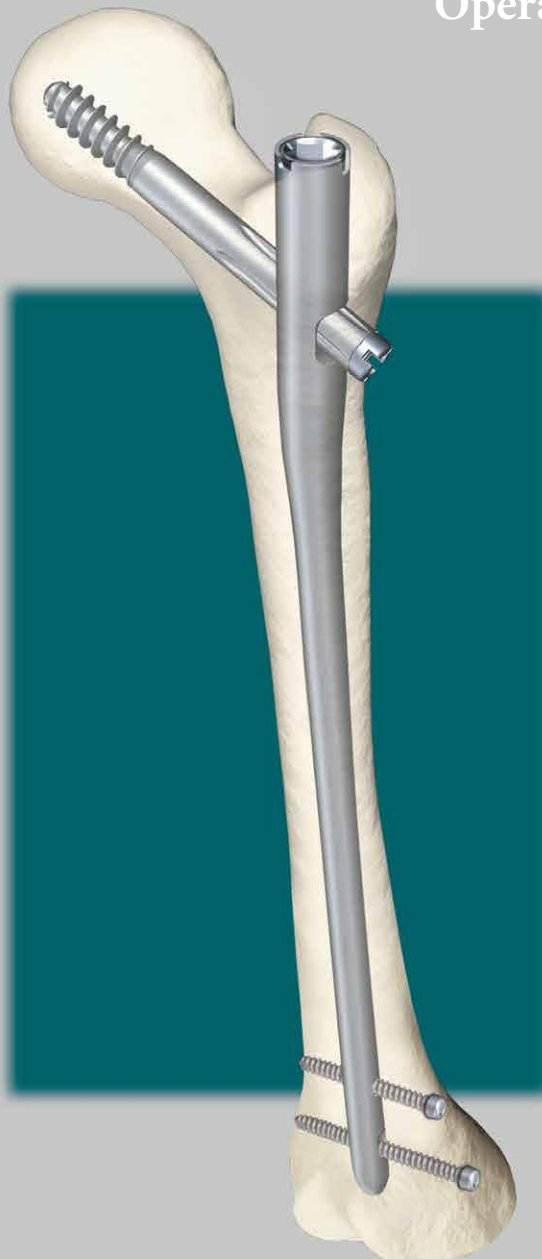**Gamma3<sup>®</sup>**

Long Nail R1.5 and R2.0

---

Operative Technique

**Hip Fractures**



# Long Nail R1.5 and 2.0

## Contributing Surgeons:

### **Prof. Kwok Sui Leung, M.D.**

Chairman of Department of Orthopaedics and Traumatology  
The Chinese University of Hong Kong  
Prince of Wales Hospital  
Hong Kong

### **Dr. Gilbert Taglang**

Head of the Trauma Department  
Center for Traumatology, Strasbourg  
France

### **Prof. Dr. med. Volker Bühren**

Chief of Surgical Services  
Medical Director of Murnau Trauma Center, Murnau  
Germany

### **Katsumi Sato M.D.Ph.D.**

Vice-Director, Chief Surgeon  
Tohoku University Graduate School of Medicine  
Tohoku Rosai Hospital, Sendai  
Japan

### **Christopher T. Born M.D.**

Professor of Orthopaedic Surgery  
Brown University, Providence, RI  
USA

### **Robert Probe, M.D.**

Division of Orthopaedic Surgery  
Scott & White Memorial Hospital, Temple, Tx  
USA

### **Prof. Dr. med. Vilmos Vécsei**

Chief of Traumatology Department  
University of Vienna, Vienna  
Austria

### **James Maxey, M.D.**

Clinical Assistant Professor  
University of Illinois College of Medicine  
Peoria, IL  
USA

---

This publication sets forth detailed recommended procedures for using Stryker Osteosynthesis devices and instruments.

It offers guidance that you should heed, but, as with any such technical guide, each surgeon must consider the particular needs of each patient and make appropriate adjustments when and as required. A workshop training is recommended prior to first surgery.

All non-sterile devices must be cleaned and sterilized before use. Follow the instructions provided in our reprocessing guide (L24002000). Multi-component instruments must be disassembled for cleaning. Please refer to the corresponding assembly/disassembly instructions.

See package insert (L22000007) for a complete list of potential adverse effects, contraindications, warnings and precautions. The surgeon must discuss all relevant risks, including the finite lifetime of the device, with the patient, when necessary.

## **Warning:**

### **Fixation Screws:**

**Stryker Osteosynthesis bone screws are not approved or intended for screw attachment or fixation to the posterior elements (pedicles) of the cervical, thoracic or lumbar spine.**

# Contents

	<b>Page</b>
<b>1. Introduction</b>	<b>4</b>
<b>2. Design of the Gamma3 System</b>	<b>5</b>
Lag Screw and Set Screw Function	6
Distal Locking Screws	7
Gamma3 System Benefits	8
<b>3. Indications, Precautions &amp; Contraindications</b>	<b>9</b>
Indications	9
Contraindications	9
Precautions	9
<b>4. Operative Technique</b>	<b>10</b>
Pre-operative Planning	10
Implant Selection	10
Patient Positioning	11
Fracture Reduction	12
Special Techniques for Fracture Reduction	13
Incision	14
Entry Point	16
Opening the Cortex	16
Preparation of Medullary Canal	17
Assembly of Targeting Device	23
Nail Insertion	26
Lag Screw Positioning using One Shot Device	28
Lag Screw Insertion	29
Pre-Drilling the lateral cortex	30
Lag Screw Fixation	34
Distal Screw Locking	38
Free-hand Technique	40
End Cap Insertion	42
Nail Extension End Caps	43
Post-operative Care and Rehabilitation	43
Extraction of the Gamma3 Implants	44
Dealing with Special Cases	46
Packaging	47
<b>References</b>	<b>49</b>

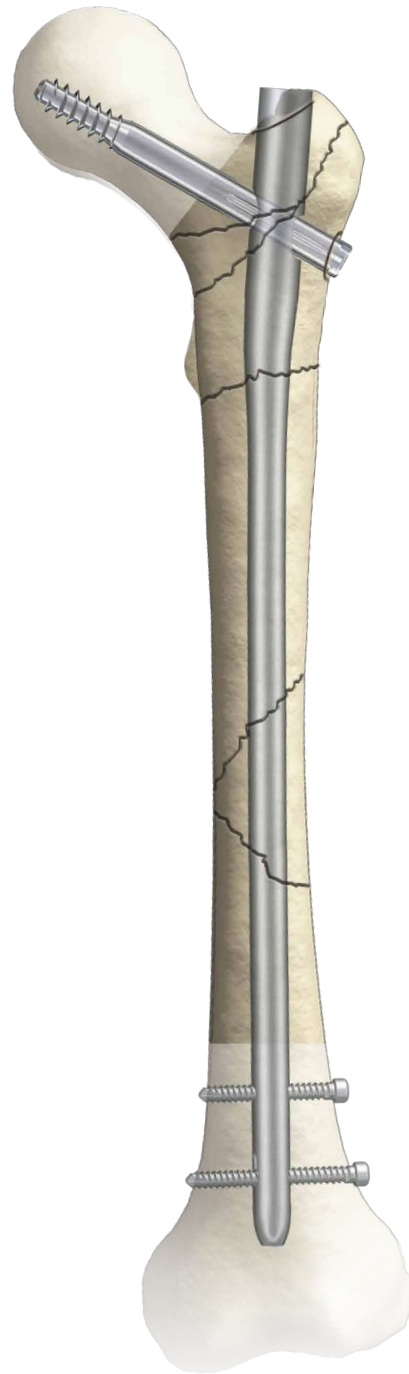# Introduction

The Gamma3 Locking Nail System is based on more than 20 years of Gamma Nail experience. This is the third generation of intramedullary short and long Gamma fixation nails.

The Evolution of the successful Trochanteric and Long Gamma Nails as well as the small stature versions followed strictly a step by step improvement based on the clinical experience and outcome from surgeons all over the world.

## **Acknowledgements:**

Our thanks are due to the many surgeons who supported the development of the new Gamma3 System, with their feedback and ideas, during worldwide panel meetings and helped the Gamma3 System to be what it is today.



# Design

## The Gamma3 System

Gamma3 Locking Nails come in 3 neck-shaft angles of 120°, 125° and 130°.

- In the following, these Gamma3 Nails are called: **Long Nail**

All nails\* use the same Lag Screws, Set Screw, distal Locking Screws and End Caps (see Fig. 1).

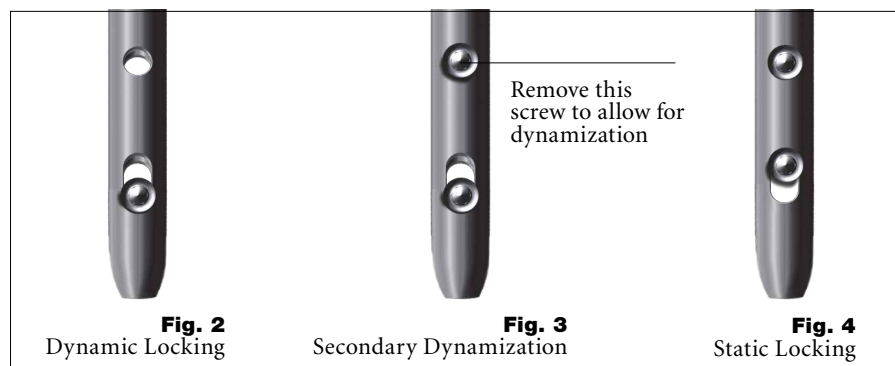
### Gamma3 Nail Long

This nail incorporates several important mechanical design features. The nail is unslotted and cannulated for Guide-Wire-controlled insertion. To facilitate conformity with the human anatomy, the Long Nail is supplied in a left and right version.

The three neck-shaft angles accommodate variations in femoral neck anatomy. The Long Nail offers the opportunity to use two distal Locking Screws that are inserted through the distal nail end to control rotation and telescoping. As shown below, the nail offers the possibility for either static, dynamic or secondary dynamic distal locking, depending on the fracture pattern.

### Long Nail Distal Locking Options

- Locking in the distal part of the oblong hole creates a dynamic locking mechanism – requires only one screw (see Fig. 2).
- One screw placed in the distal part of the oblong hole and the other in the round hole. If dynamization is required after a period of time, the screw, placed in the round hole, has to be removed – requires two screws (see Fig. 3).
- One screw placed in the round hole and the other is placed in the proximal part of the oblong hole – requires two screws (see Fig. 4).



### Technical Specifications:

- Material:** Titanium alloy with anodized type II surface treatment.
- Nail length:** 260mm to 480mm, in 20mm increments, shorter or longer nails are available on request
- Nail diameter:**  
proximal: 15.5mm,  
distal: R1.5: 10mm, 11mm, 13mm, 15mm  
R2.0: 11mm, 13mm, 15mm
- Proximal Nail angle range:** 120°, 125°, 130°
- M-L bend for valgus curvature:** 4 degrees
- Proximal anterversion of 10°**
- End Caps** 0mm, +5mm and +10mm
- Antecurvature radius R1.5m and R2.0m of the shaft**
- Distal locking holes (round and oblong)** for 5mm screws; up to 5mm dynamization is possible



**Fig. 1**

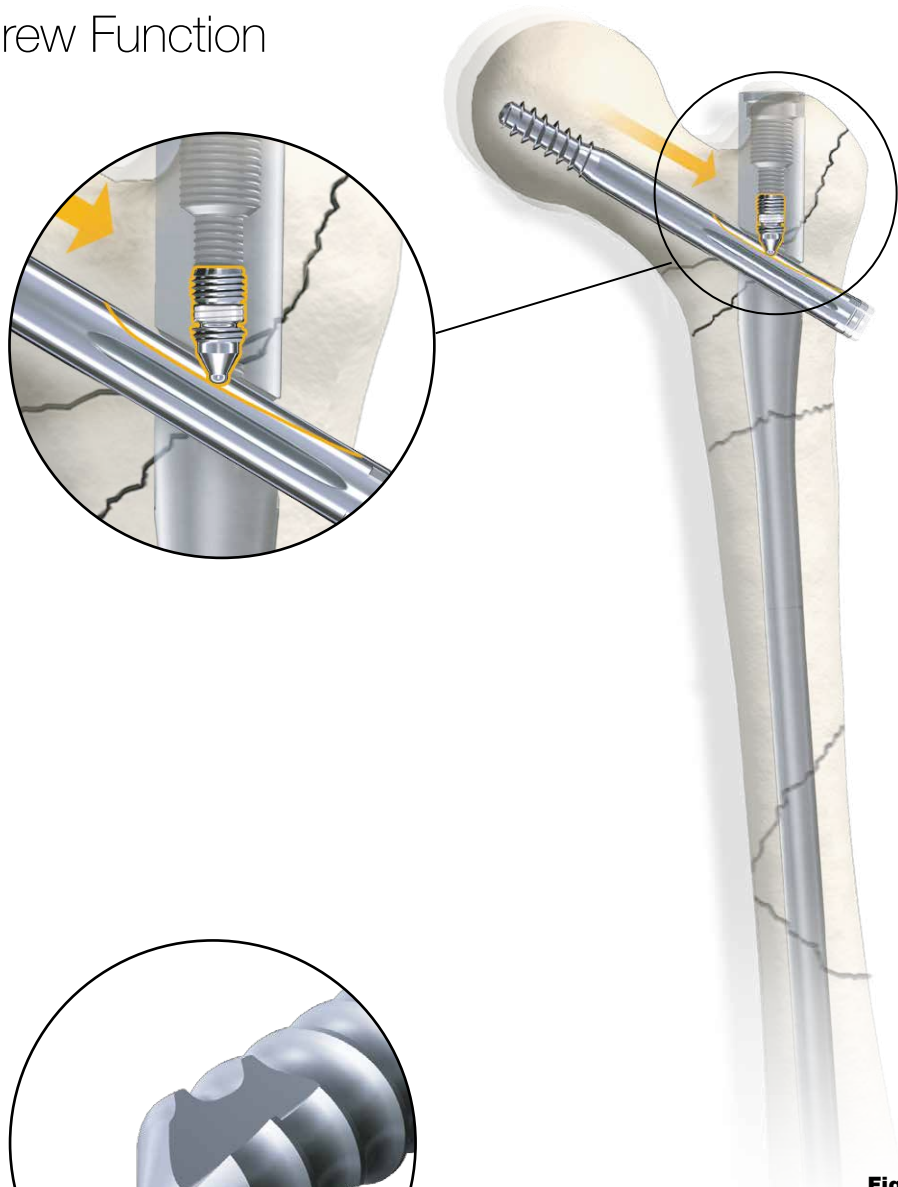
\* Each nail is supplied sterile packaged together with a Set Screw in one box.

# Design

## Lag Screw and Set Screw Function

### Technical Specifications

- Lag Screw diameter: 10.5mm
- Lag Screw lengths: 70–130mm in 5mm increments
- Lag Screw design for high load absorption and easy insertion
- Asymmetrical depth profile to allow the Lag Screw to slide in the lateral direction only (see orange arrow on Fig. 5).
- Self retaining Set Screw to protect the Lag Screw against rotation and simultaneously allowing sliding of the Lag Screw laterally.



**Fig. 5**  
Lag Screw Stabilization System

## Distal Locking Screws

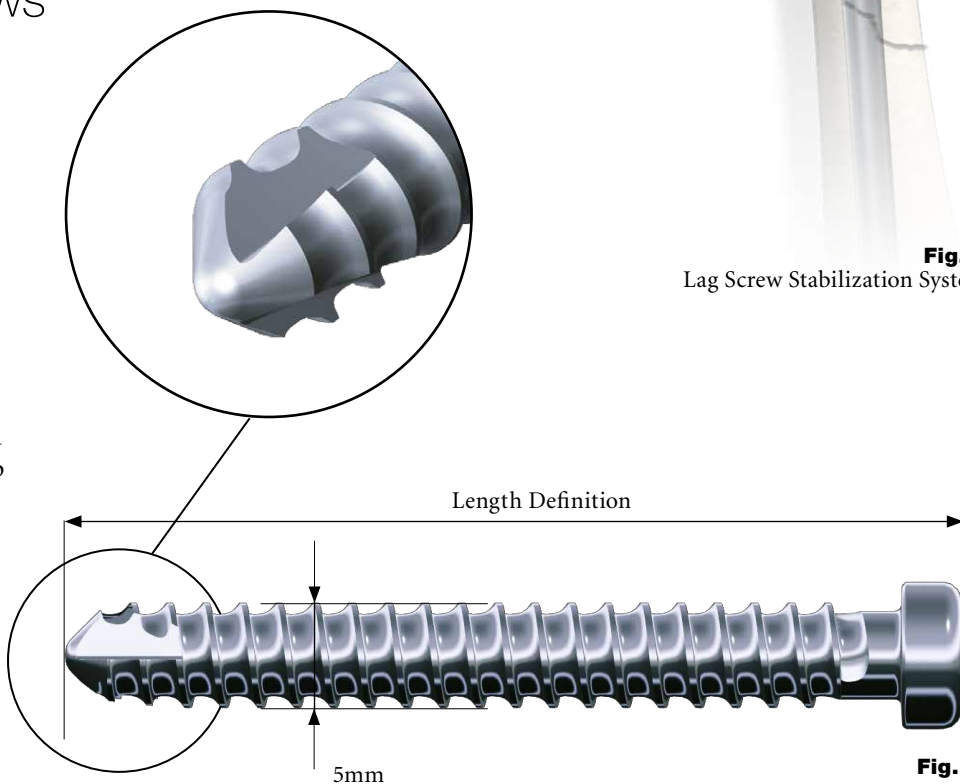
### Length Definition of the Distal Locking Screw

The distal Locking Screw is measured from head to tip (Fig. 6).

Dimensions are nominal.

### Technical Specifications

- Distal Locking Screw Diameter: 5mm.
- Distal Locking Screw lengths ranging from 25–50mm, in 2.5 and 5mm increments. Longer screws up to 120mm are available on request.
- Fully threaded screw design. Partially threaded screws are available on request.



**Fig. 6**

# Indications, Precautions & Contraindications

## Indications

The Long Length Gamma3 Nail is intended for fixation of stable and unstable femoral fractures occurring from the base of the femoral neck extending distally to a point approximately 10 cm proximal to the intercondylar notch, including fractures of the basilar neck, intertrochanteric fractures, pertrochanteric fractures, subtrochanteric fractures and femoral shaft fractures.

Indications may include fractures from trauma, nonunion, malunion, pathological fractures in both trochanteric and diaphyseal areas, impending pathological fractures, (including prophylactic use), tumor resections, and revision procedures.

## Precautions

Stryker Osteosynthesis systems have not been evaluated for safety and use in MR environment and have not been tested for heating or migration in the MR environment, unless specified otherwise in the product labeling.

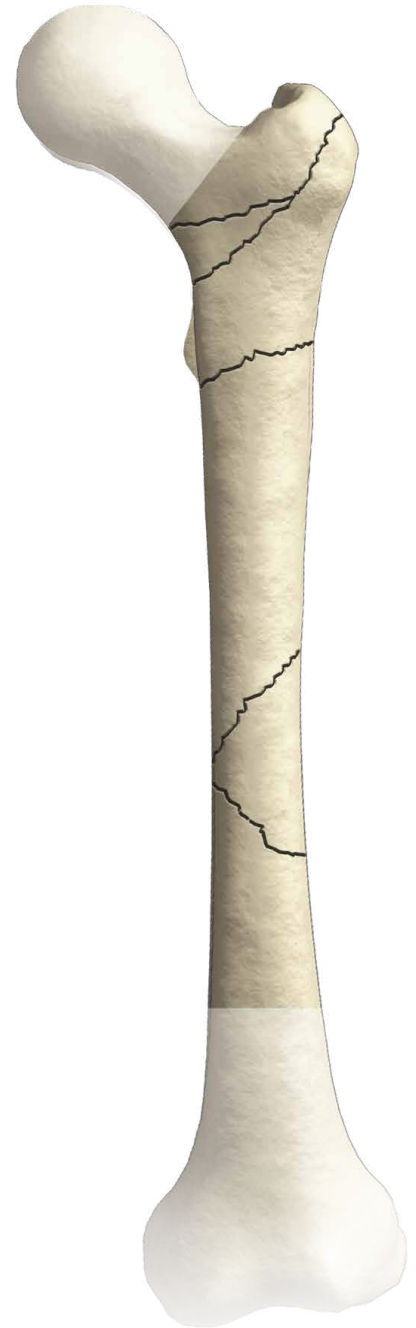
## Contraindications

Contraindications are medial neck fractures.

### Caution:

**The Gamma Nail is designed for temporary implantation until the bone consolidation occurs. Therefore, if no bone consolidation occurs or if consolidation is not sufficient, the system may fail. The aim of post-operative care must be to ensure the promotion of bone consolidation. The Gamma Nail is not intended for full weight bearing in patients with complex unstable fractures until sufficient bone consolidation is confirmed in the follow up X-rays.**

This operative technique has been devised in consultation with leading surgeons in many countries to be a basic guide, particularly for less experienced users of the Gamma3 System. It is acknowledged that several alternative approaches to certain elements of the procedure are available, and may have advantages for particular situations or surgeons.



**Fig. 8**

# Operative Technique

## Pre-operative Planning

The Gamma3™ Nail with a 125° nail angle may be used in the majority of patients.

Where such variations in femoral anatomy require an alternative, the following chapter describes how to select the optimal implant size.

## Implant Selection

X-ray templates are very helpful during preoperative planning. Use the X-ray Template (Fig. 9a for long nails to select the correct implant and the optimal nail angle.

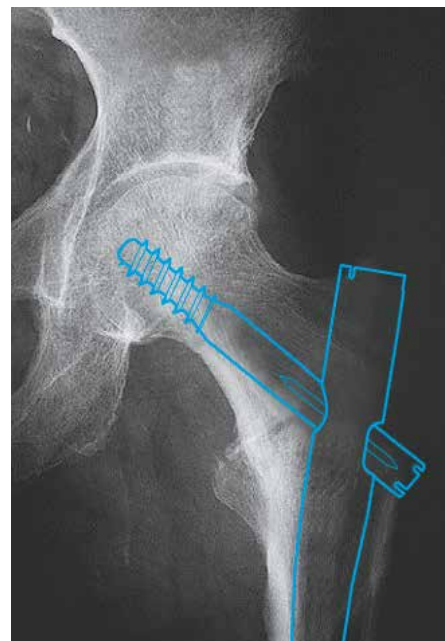
This template shows the true implant size at a magnification of 10% in anterior-posterior view. The X-rays should be taken at this magnification (10%) for an optimum surgical outcome (see Fig. 9). If accurate anatomical reduction has been achieved, the X-ray can be taken from the fractured hip or from the contralateral side.

Alternatively the femoral neck angle, i.e. the angle between the femoral shaft mid-axis and the femoral neck mid-axis, could be measured using a goniometer. The nail length may also be determined intraoperatively using the Guide Wire Ruler together with the Guide Wire.

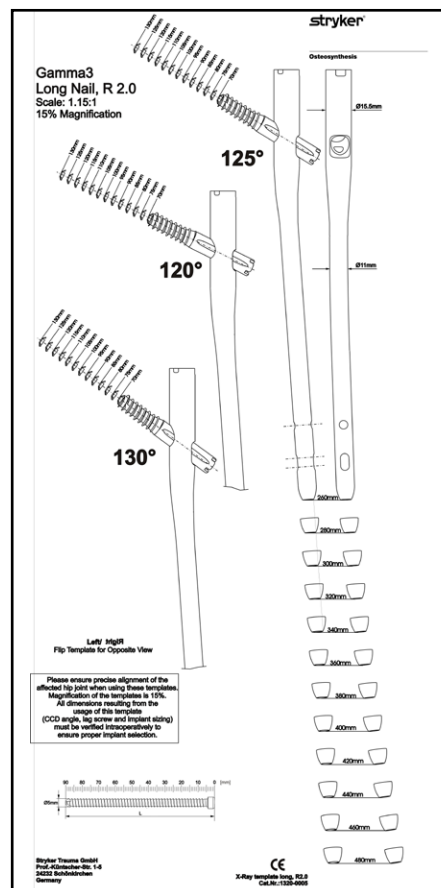
In case the X-Ray Templates do not show an anatomical fit with the bone, a different implant solution should be considered.

### Note:

- Please ensure precise alignment of the affected hip joint when using these templates. Template magnification is 10%. All dimensions (nail angle and implant sizing) resulting from using these templates must be verified intraoperatively to ensure proper implant selection.
- Stryker Imaging offers also the Advanced Case Plan including digital template for Gamma3 System as an alternative.



**Fig. 9**  
X-Ray in a-p view, showing implant



**Fig. 9a**  
Gamma3 Long Nail R1.5 X-Ray Template, 10%  
(Ref. No 1320-0009)



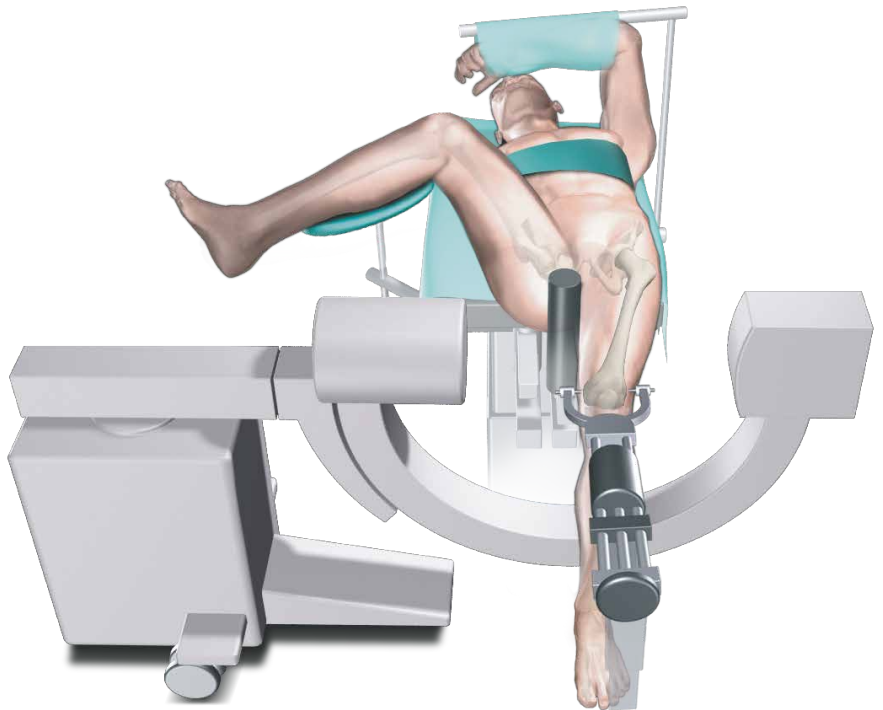
# Operative Technique

## Patient Positioning

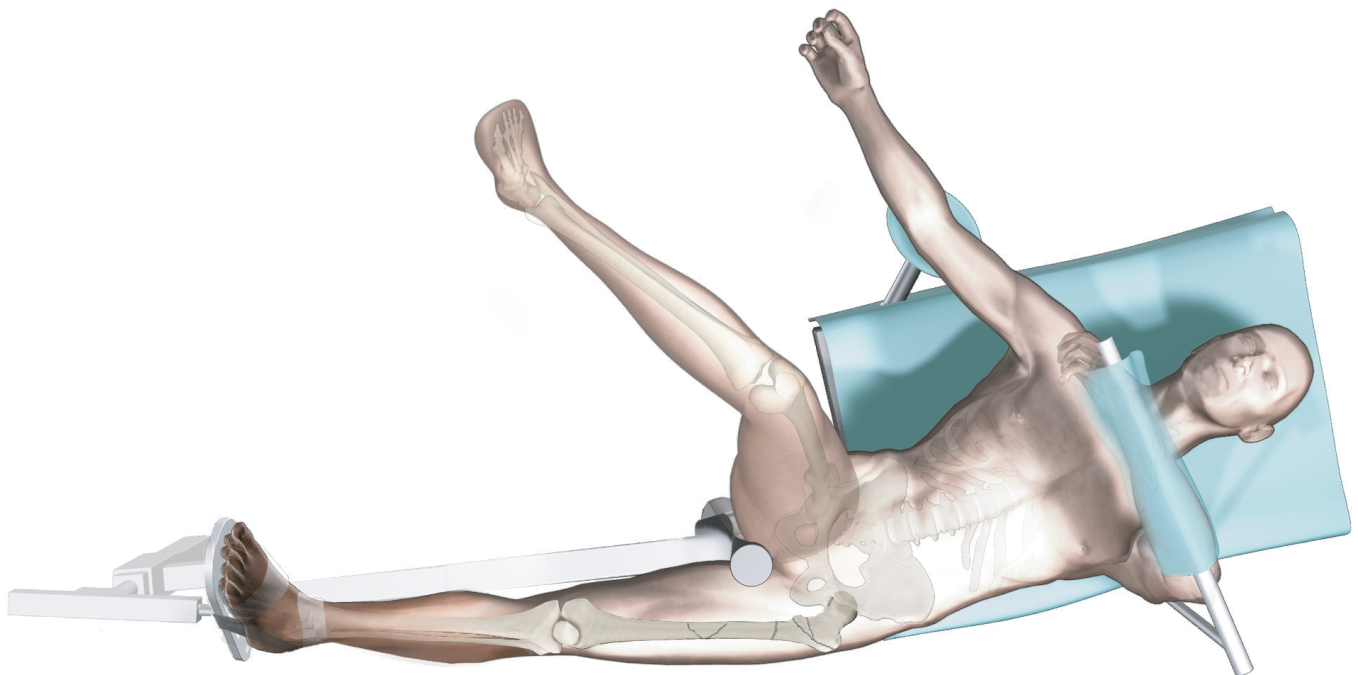
The procedure for patient positioning is usually similar to that of a subtrochanteric fracture, however, in fractures that are particularly difficult to reduce, a transcondylar sterile Steinmann pin may be used. The pin is fixed directly to the orthopaedic table by an adaptable stirrup, and traction is applied until anatomical reduction in the A-P view is obtained (Fig. 10).

The patient is placed in a supine position on the fracture table and closed reduction of the fracture is recommended (Fig. 11).

Traction is applied to the fracture, keeping the leg straight. The upper trunk should be flexed to the opposite side so that the fracture can be reduced by not too much adduction of the lower limb. It also gives easy access to the greater trochanter.



**Fig. 10**



**Fig. 11**

# Operative Technique

## Fracture Reduction

Maintaining traction, the leg is internally rotated 10–15 degrees to complete fracture reduction; the patella should have either a horizontal or slightly inward position (Fig. 12).

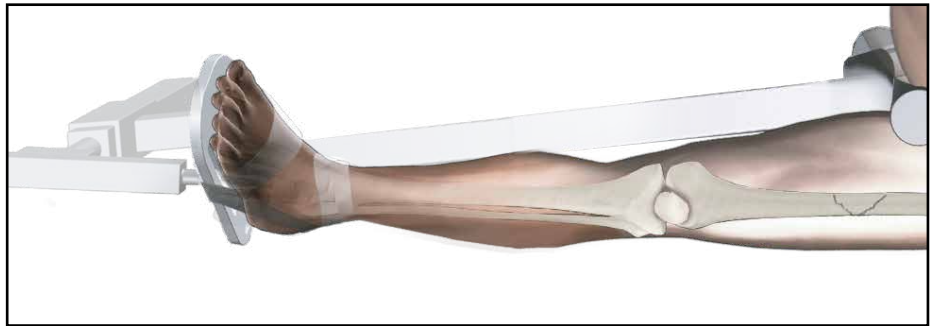
Position the image intensifier so that anterior-posterior and mediolateral views of the trochanteric region of the affected femur can be easily obtained. This position is best achieved if the image intensifier is positioned so that the axis of rotation of the intensifier is centered on the femoral neck of the affected femur (Fig. 13). The views of the distal femur should also be easily obtained for distal locking.

It is important to ensure that a view of both the distal and proximal tips of the nail can be obtained during the procedure without obstruction by the traction table.

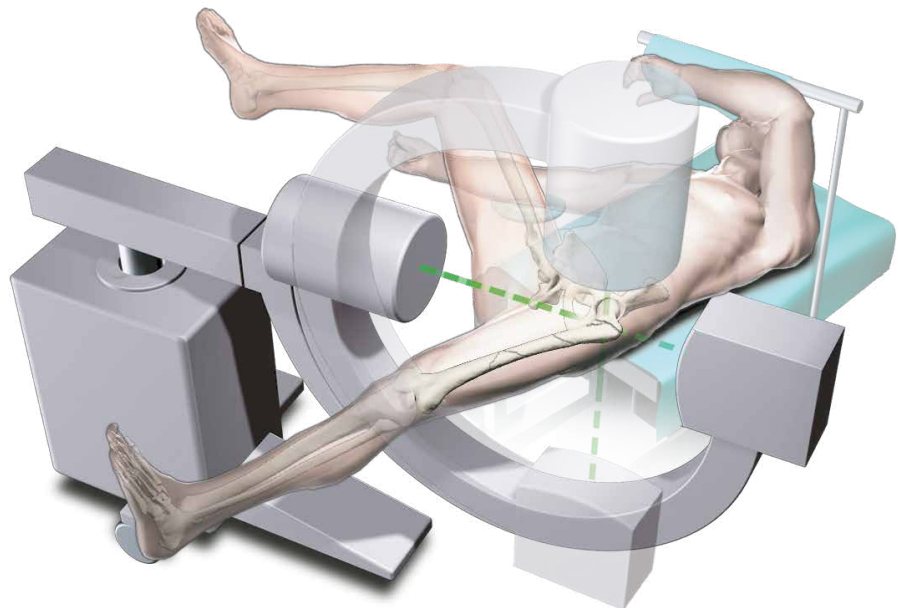
The patient is then prepared and draped as for standard femoral nailing procedures. When positioning the drapes, bear in mind that the incision will be more proximal.

### Note:

Reduction should be achieved as anatomically as possible. If this is not achievable, reduction should be achieved at least in one plane. Reduction in the other plane may be achieved with the Gamma3 Nail during insertion.



**Fig. 12**



**Fig. 13**

# Operative Technique

## Fracture Reduction

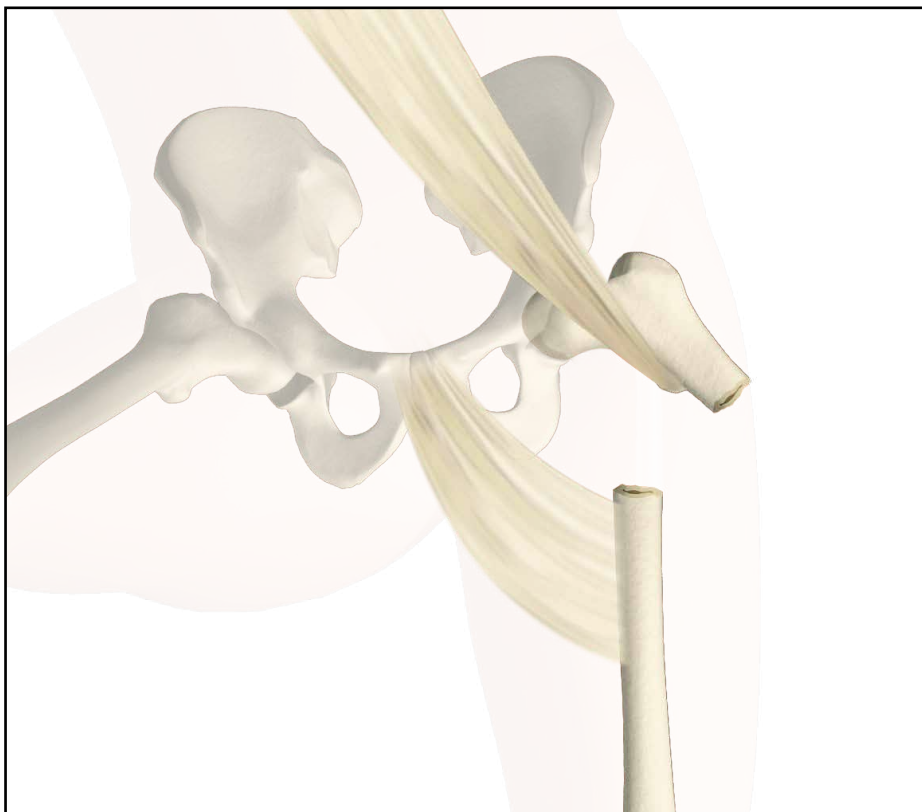
### Special Techniques

For specific situations, special techniques have been developed for fracture reduction, that are explained below.

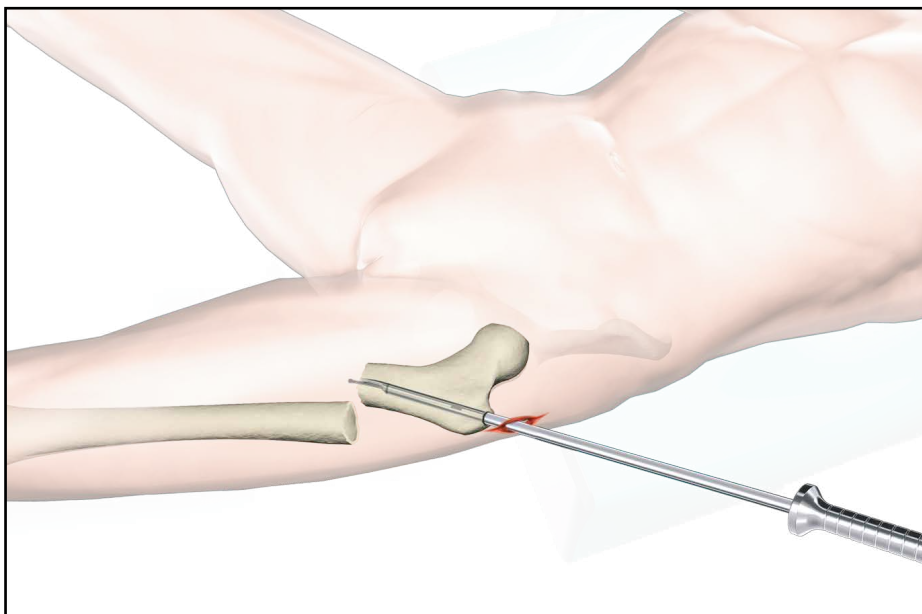
To counter this misalignment, the trunk is turned to the opposite side and held in position by a thoracic rest or by a large drape. This tightens the gluteus medius muscles and relaxes the psoas, externally rotating the proximal fragment into alignment and exposing the trochanter for easier introduction of the nail. The fractured limb is kept straight, with the knee in flexion (Fig. 14), using the stirrup to avoid adduction. This position helps to align the distal portion. Reduction is confirmed in the AP view.

Subtrochanteric fractures cannot always be reduced during positioning in the lateral view, because the proximal fragment is drawn forward by tension from the psoas muscles. This may be reduced during surgery by using the Universal Rod (Fig. 15).

Care must be taken when introducing the implant as the proximal fragment may rotate during insertion.



**Fig. 14**



**Fig. 15**

# Operative Technique

## Incision

Incisions may be developed in different manners. Two alternatives will be described below.

### Alternative 1:

The tip of the greater trochanter may be located by palpation (Fig. 16) and a horizontal skin incision of approximately 2–3cm is made from the greater trochanter in the direction of the iliac crest (Fig. 17).

In larger patients the incision length may need to be longer, depending on the size of the patient.

A small incision is deepened through the fascia lata, splitting the gluteal muscle approximately 1–2cm immediately above the tip of the greater trochanter, thus exposing its tip. A self-retaining retractor, or tissue protection sleeve is put in place.

### Alternative 2:

A long and thin metal rod (e.g. Screw Scale, Long) is placed on the lateral side of the leg. Check with the image intensifier, using L-M view (Fig. 18), that the metal rod is positioned parallel to the bone in the center of the proximal part of the femoral canal (Fig. 19a). A line is drawn on the skin (Fig. 19).

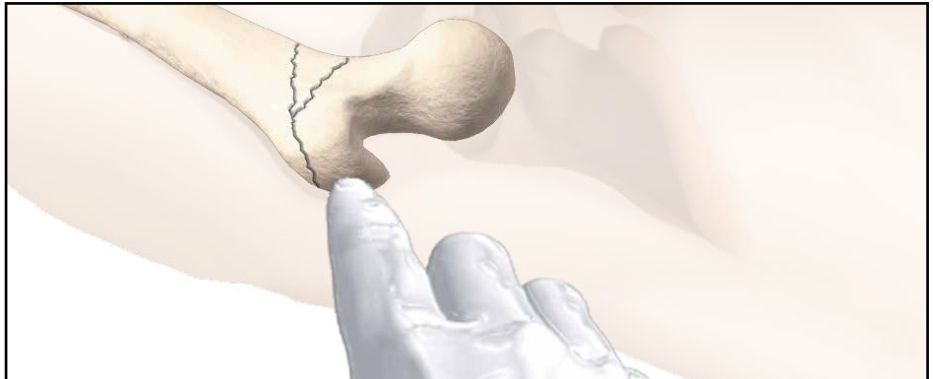

Fig. 16

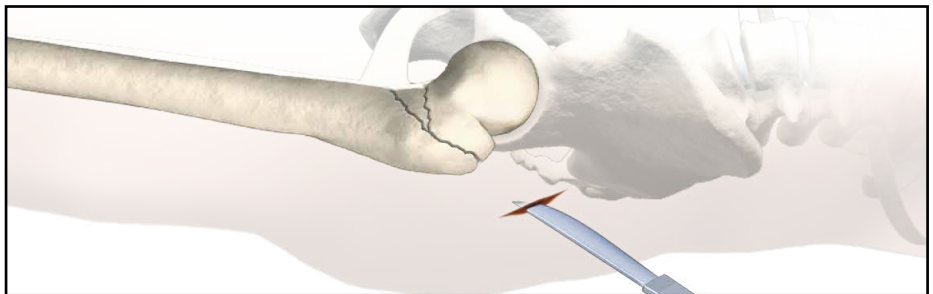


Fig. 17

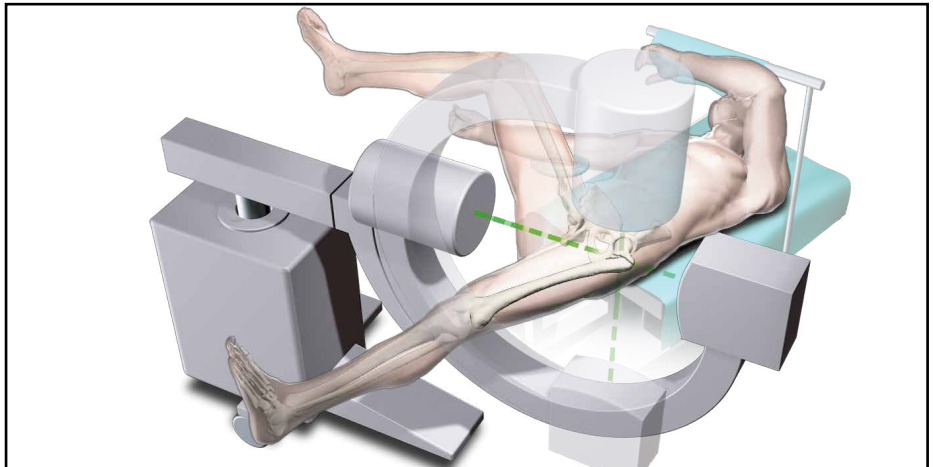


Fig. 18

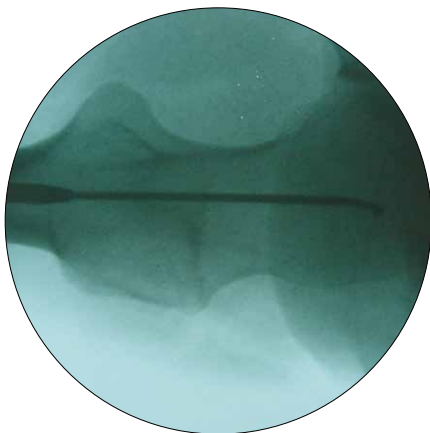


Fig. 19a


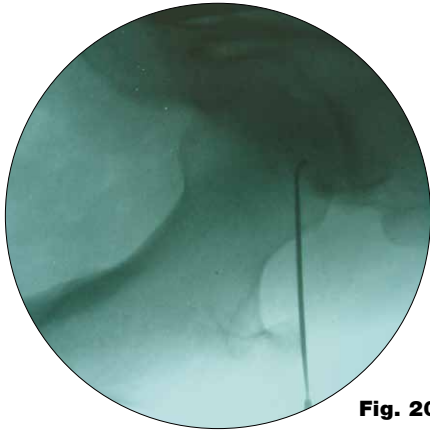


Fig. 19

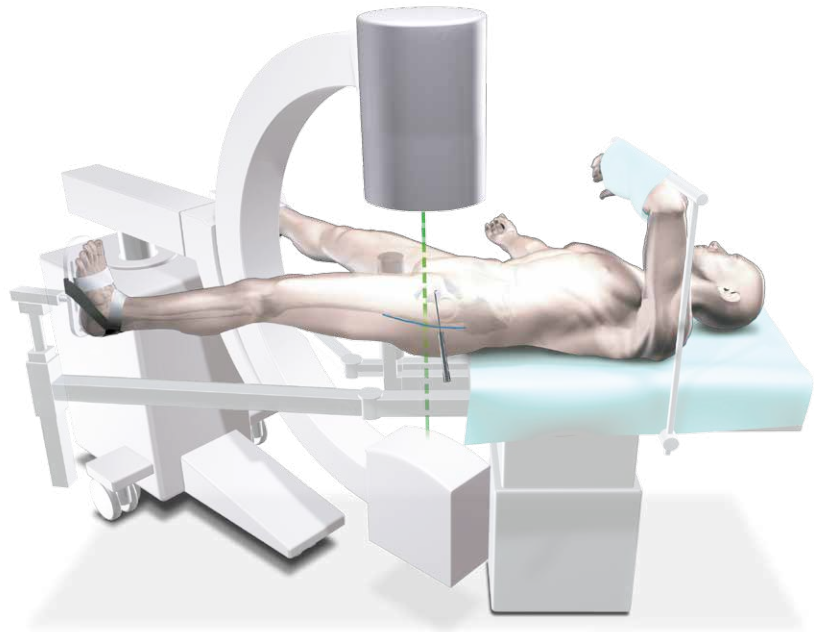


# Operative Technique

The C-arm is turned approx. 90° to provide an A-P image of the tip of the trochanter using the metal rod as shown in Fig. 20 and 20a.



**Fig. 20a**



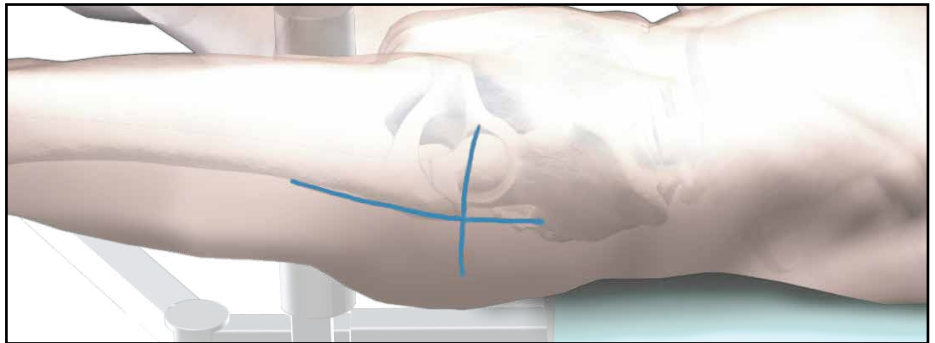
**Fig. 20**

A vertical line is drawn onto the skin (Fig. 21). The intersection of the lines indicates the position for the entry point of the nail. This is usually the anterior third of the tip of the greater trochanter as shown in Fig. 25, next page.

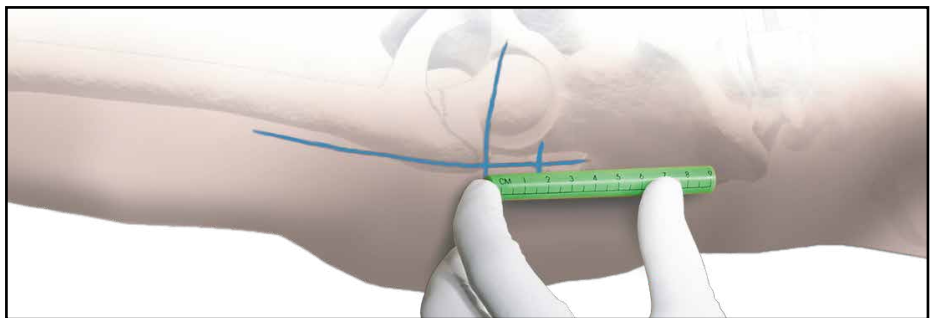
The skin incision is made cranially to the indicated intersection, following the sagittal line in cranial direction.

The distance between the intersection and the starting point for the incision differs, depending on the obesity of the patient. Under normal conditions it is a distance of approximately 2 cm (Fig. 22).


A small skin incision is made as described in Alternative 1 and shown in Fig. 23.



**Fig. 21**



**Fig. 22**



**Fig. 23**

# Operative Technique

## Incision

Using a finger, the tip of the trochanter should be felt easily (Fig. 24).

## Entry Point

The correct entry point is located at the junction of the anterior third and posterior two-thirds of the tip of the greater trochanter and on the tip itself (Fig. 25).

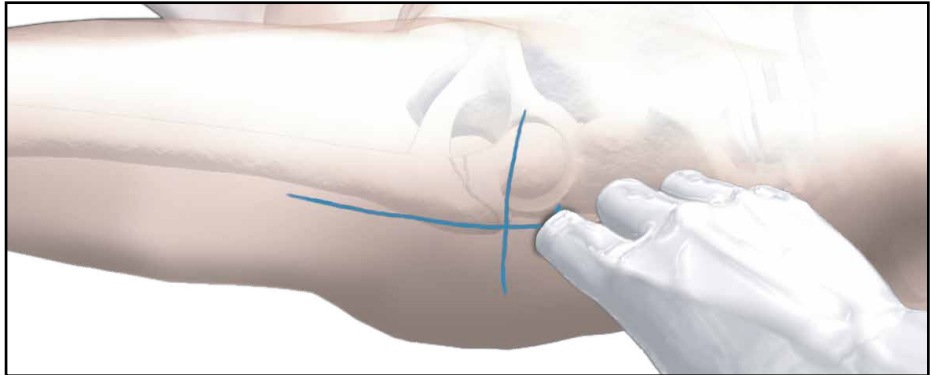
## Opening the Cortex

The medullary canal has to be opened under image intensification. The use of the cannulated Curved Awl (Fig. 26) is recommended if conventional reaming or the One Step Conical Reamer will be used to prepare the canal for the nail.

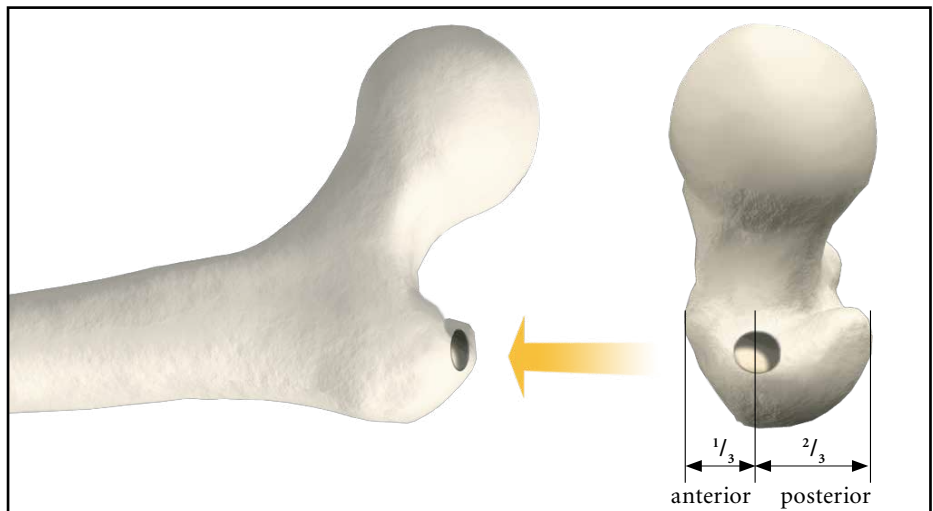
### Caution:

**During opening the entry point with the Awl, dense cortex may block the tip of the Awl.**  
**An Awl Plug (1806-0032) can be inserted through the Awl to avoid penetration of bone debris into the cannulation of the Awl Shaft.**

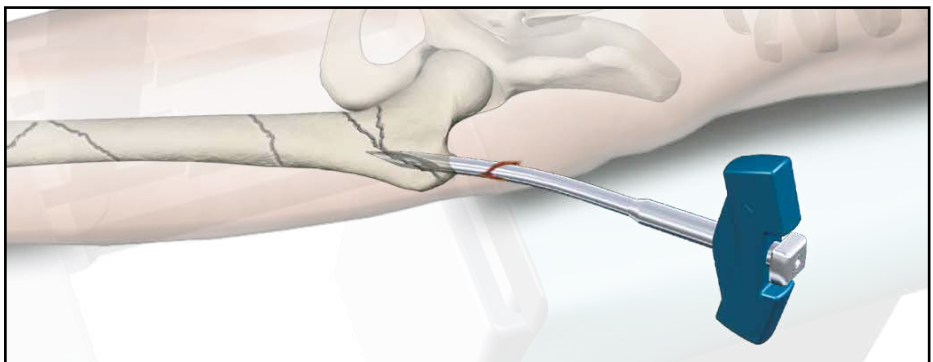
The optional Rasp Awl combines the feature of the Rasp and Awl to prepare the proximal femur for the Gamma3 Nail. It may provide an option to open the proximal femur cavity without further reaming (Fig. 27).



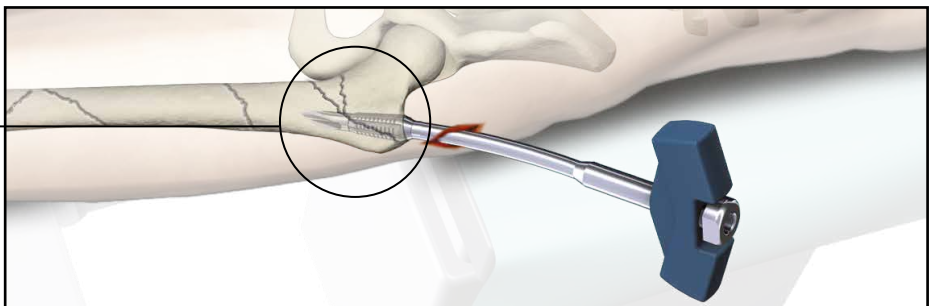
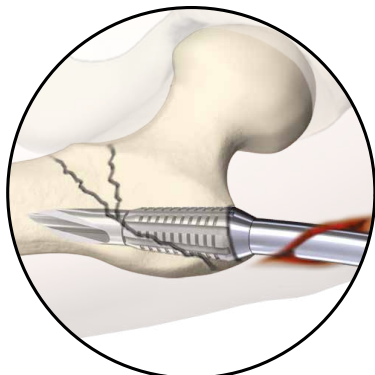
**Fig. 24**



**Fig. 25**



**Fig. 26**



**Fig. 27**

# Operative Technique

## Preparation of the Medullary Canal

The Gamma3 System includes four options to prepare the medullary canal. These options are described below.

### Alternative 1:

#### Reaming the Medullary Canal

A 3mm ball-tipped Guide Wire is recommended as a reamer guide. Pass the reamer Guide Wire through the cannulated curved awl into the shaft of the femur as shown, using the Guide Wire Handle (Fig. 28).

Rotating the Guide Wire during insertion makes it easier to achieve the desired position in the middle of the medullary canal.

Flexible reamers are used to ream the shaft of the femur in stages starting from 9mm diameter and increasing in 0.5mm increments.

The canal should be reamed at least 2mm larger than the distal diameter of the nail. In some narrow medullary canals, reaming may be necessary to achieve this (Fig. 29).

When reaming is performed, the entire femoral canal should be over-reamed down through the isthmus, in order to avoid stress riser in the bone.

In order to accommodate the proximal part of the Gamma3 Long Nail, the subtrochanteric region must be opened up to 15.5mm (Fig. 30). This can be done either by reaming with the Stryker Bixcut Reaming System (Fig. 28a) or, alternatively, with the One Step Conical Reamer. For soft tissue protection, the Conical Reamer Sleeve should be used during reaming.

### Warning:

Care must be taken with flexible reamers to ensure that the Guide Wire is not displaced laterally during reaming. This could lead to resection of more bone on the lateral side, which in turn would lead to an offset position for the nail and a risk of shaft fracture.

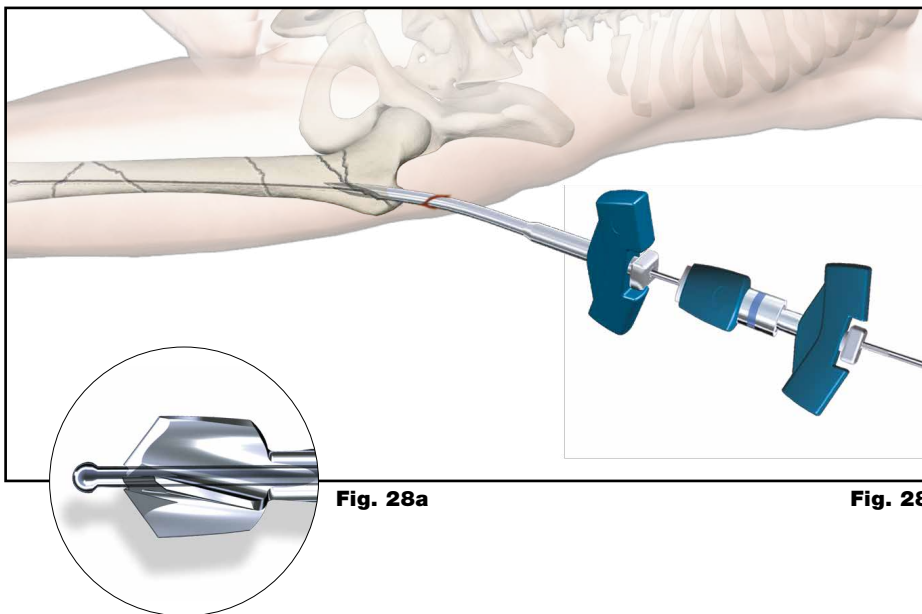


Fig. 28a

Fig. 28

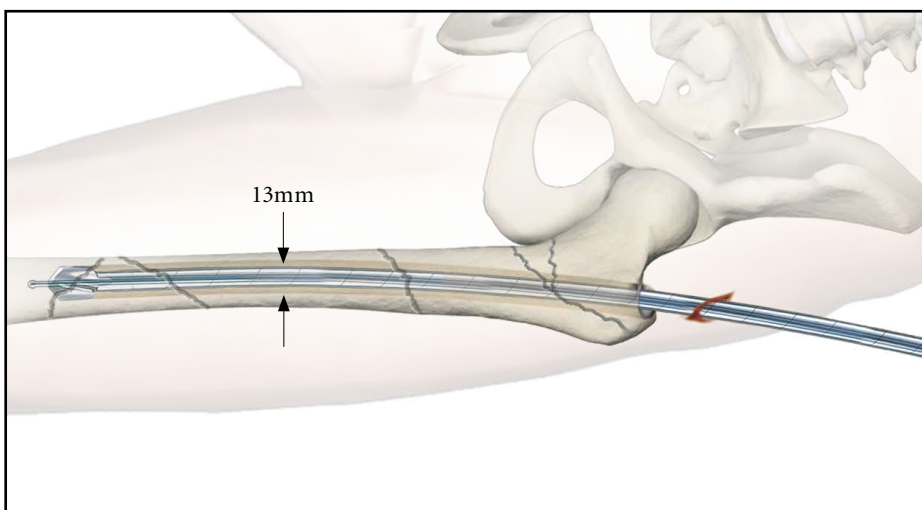


Fig. 29

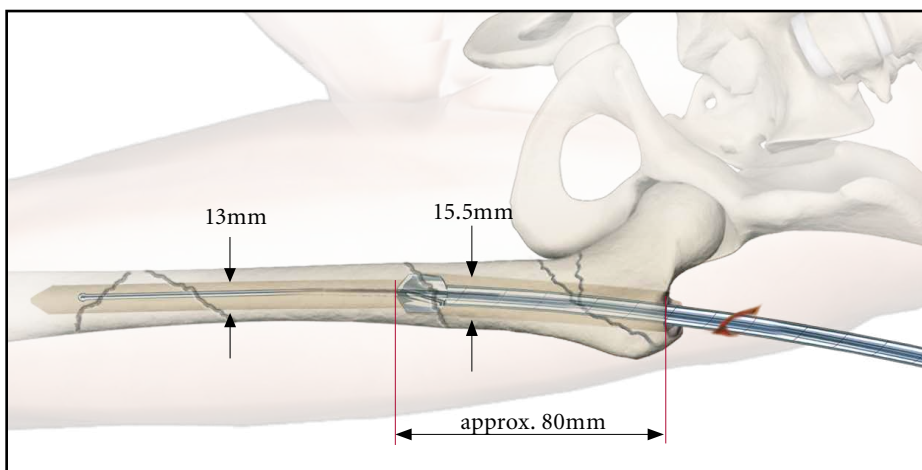


Fig. 30

# Operative Technique

## Alternative 2: One Step Conical Reamer

The One Step Conical Reamer is an optional instrument and has been developed to provide surgeons with another option to prepare the proximal canal of the trochanter using only one drilling step.

Using Gamma3 Long Nails, it is recommended to ream the medullary canal all the way down to the condyle area, at least up to a diameter of 13mm.

After skin incision and positioning of the Guide Wire as described above, the Trocar or Multi Hole Trocar is inserted into the Reamer Sleeve to protect the soft tissue during insertion. Push the Trocar (use center hole, if Multi Hole Trocar is used) and Sleeve Assembly down over the 3mm Guide Wire to the tip of the trochanter (Fig. 31).

### Warning:

**The One Step Conical Reamer is a front and side cutting instrument and should be used with great care to ensure that the sharp edges of the reamer do not damage intact bone inadvertently.**

If a 3.2mm K-Wire was used, it should be replaced by a Guide Wire afterwards

### Entry Point Optimization

The Entry Portal can also be made without using the awl. A 3.2mm K-Wire is placed through the tip of the trochanter.

If you find that the K-Wire is not positioned in the optimal position, it may easily be corrected using a second K-Wire in combination with the Multi Hole Trocar.

The Multi Hole Trocar has a special design for more precise insertion. In addition to the central hole, 4 other holes are located eccentrically at different distances from the center (Fig. 32) to easily revise insertion of the guiding K-Wire in the proper position (Entry Point).

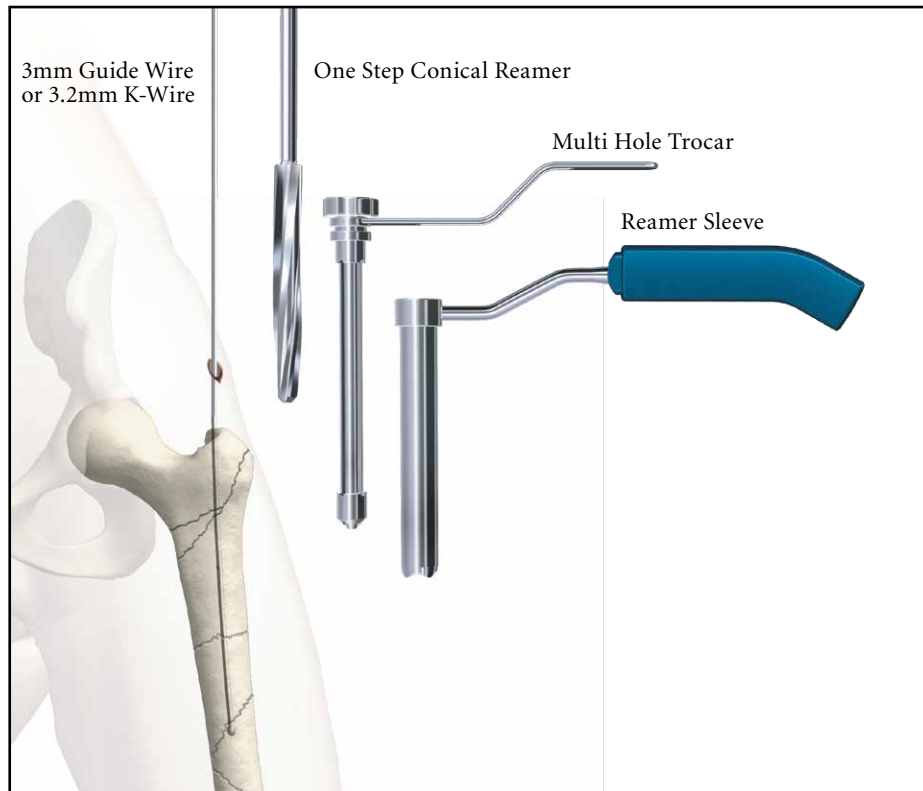


Fig. 31

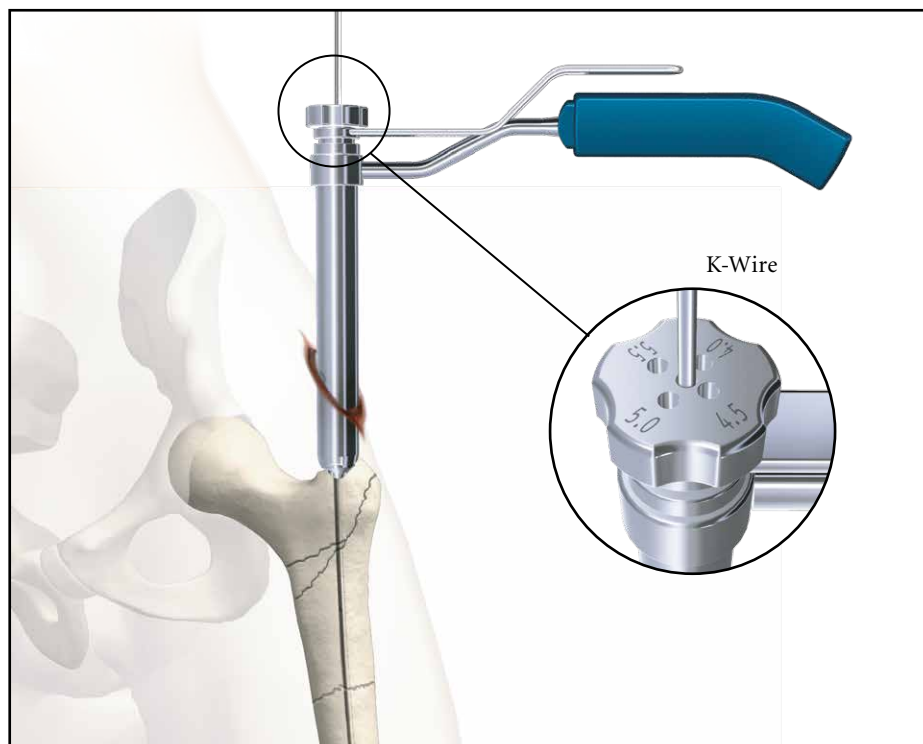


Fig. 32

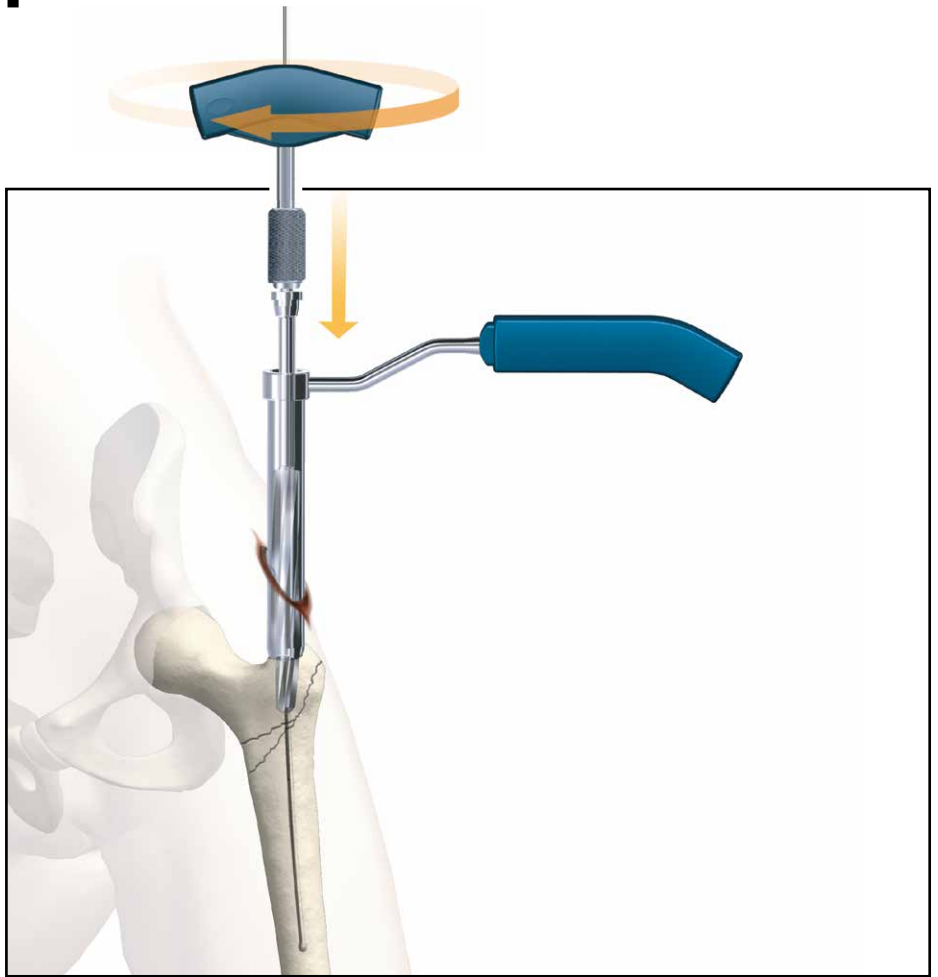


# Operative Technique

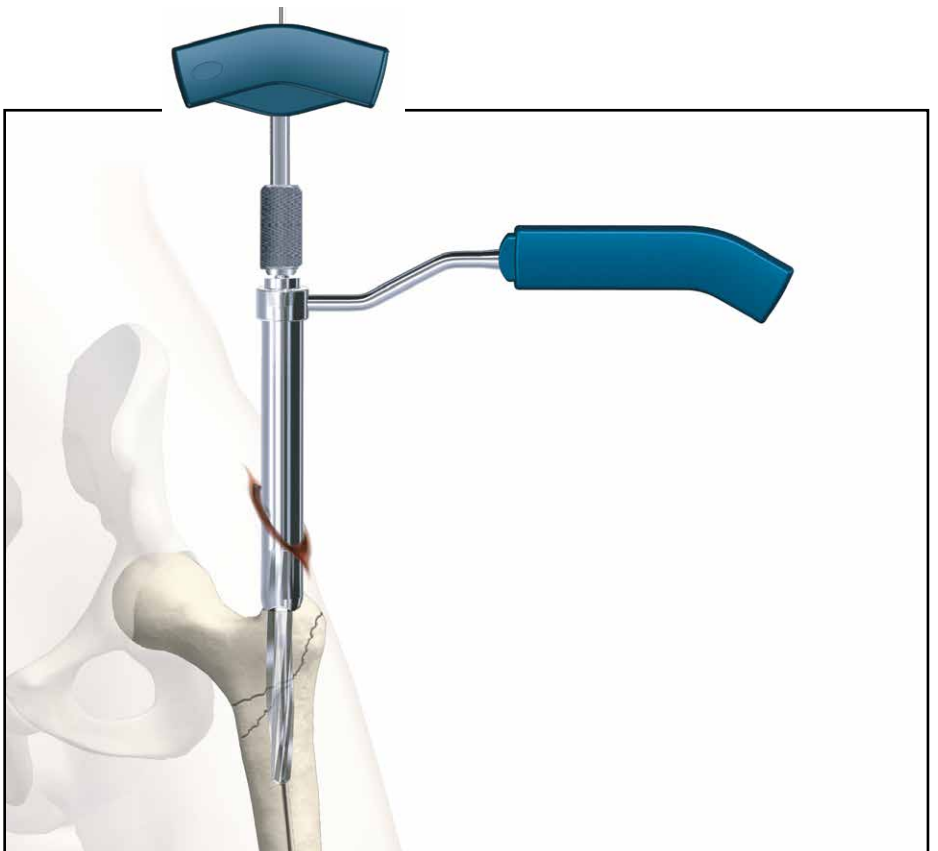
The Trocar is then removed and the One Step Conical Reamer is connected to the T-Handle and slid over the Guide or K-Wire to the tip of the trochanter. With gentle clockwise turning and pushing movements, the Conical Reamer will drill into the proximal part of the trochanter (Fig. 33 and 34) and prepare the canal for the proximal part of the Gamma3 Nail. The One Step Conical Reamer stops when the correct depth is reached. If a 3.2mm K-Wire was used it should be replaced by a Guide Wire now.

## Caution:

**3.2mm K-Wires are not intended for re-use. They are single use only. K-Wires may be damaged or be bent during surgical procedures. Therefore, please do NOT use the same K-Wire for Lag Screw insertion.**



**Fig. 33**



**Fig. 34**

# Operative Technique

## **Alternative 3: Cannulated Cutter**

### **Opening the cortex**

The Cannulated Cutter is a front cutting device used to prepare the proximal part of the femur for the Gamma3 Long Nail.

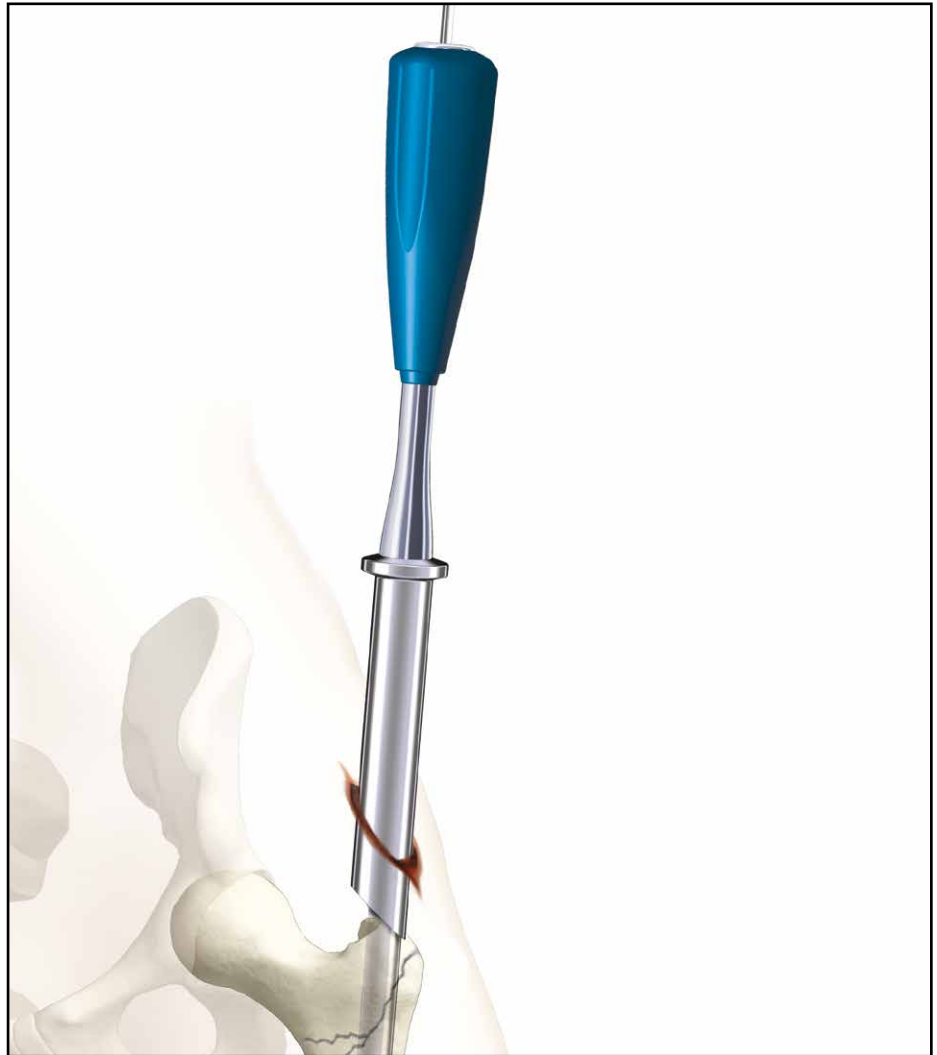It provides surgeons with an advanced option to open the proximal femur cavity without reaming. Especially in older patients it may reduce the requirement for reaming of the femoral cavity. For the Long Nail, it is recommended to ream the complete femur all the way down to the condyle area up to a diameter of at least 13mm.

The Cannulated Cutter is guided over a solid 4mm Guide Pin. The fixation of this Guide Pin in the bone allows for an optimal placement for the Cannulated Cutter (Fig. 35 to 36).

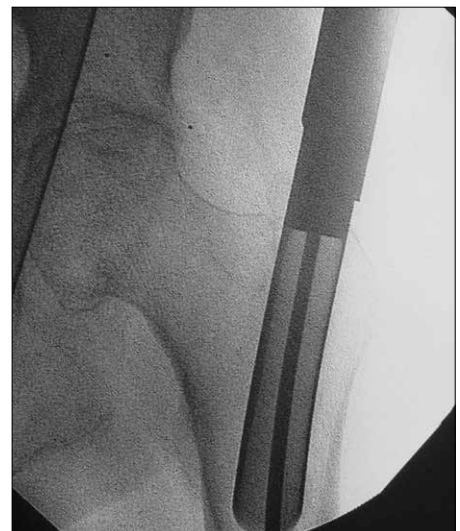
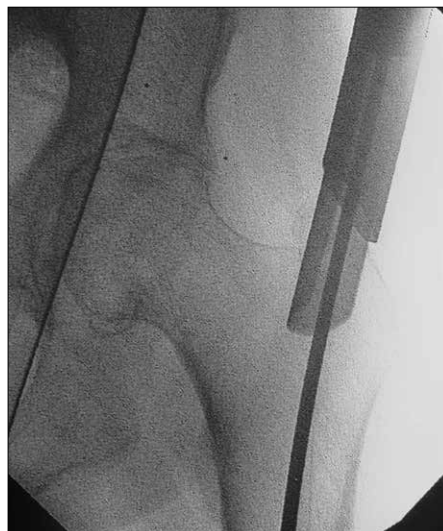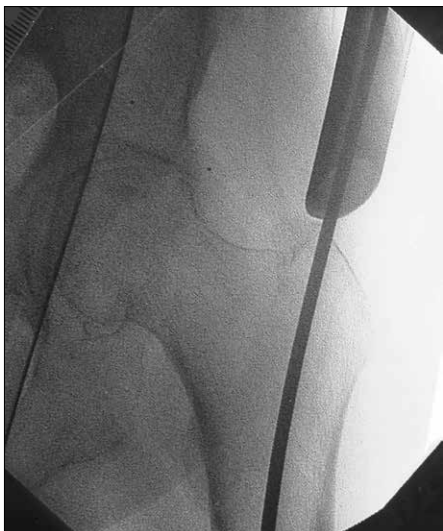This device allows for easy collection of bone graft material which might be helpful in difficult healing conditions.

### **Caution:**

When the Cannulated Cutter is used, do not open the cortex with the Awl, because the Awl usually creates larger holes than 4mm. The 4mm Guide Pin needs bony stability to provide optimal cutting performance of the Cannulated Cutter.



**Fig. 35**



**Fig. 36**

# Operative Technique

## **Alternative 4: Crown Drill**

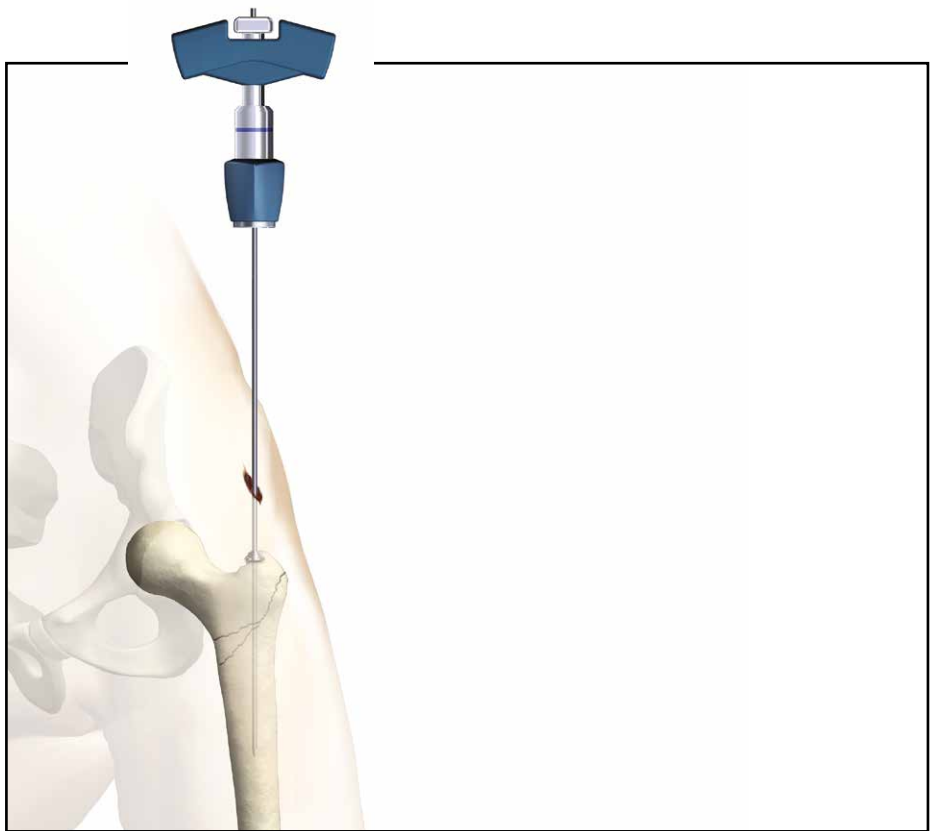
The Crown Drill is a front cutting device used to prepare the proximal part of the femur for the Gamma3 Nail 180. It may provide an option to open the proximal femur cavity without reaming. Especially in older patients, the Crown Drill may reduce the requirement for reaming of the femoral cavity.

Insert the K-Wire with Washer through a small incision using the Guide Wire Handle until the washer reaches the surface of the greater trochanter (Fig. 37).

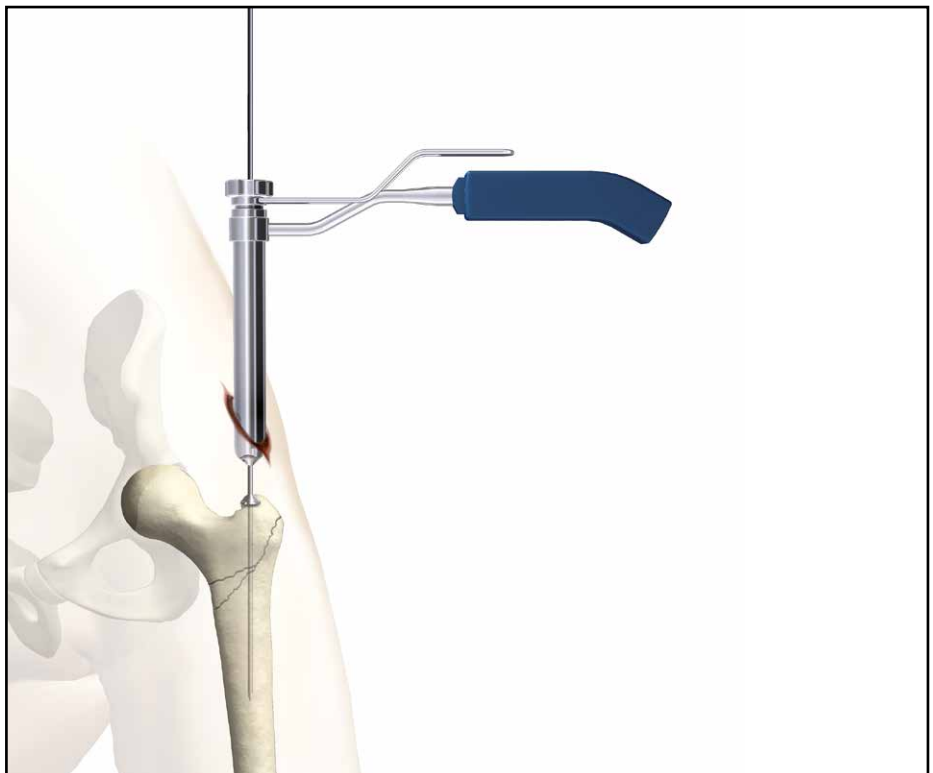
Then insert the assembled Trocar and the Reamer Sleeve over the K-wire until the tip of the Trocar reaches the Greater Trochanter (Fig. 38).

### **Caution:**

**Do not open the cortex with the Awl when using the Crown Drill, as the Awl creates a hole larger than 3.2mm. The 3.2mm K-Wire needs bony stability to provide optimal Crown Drill cutting performance.**



**Fig. 37**



**Fig. 38**

# Operative Technique

Remove the Trocar and then connect the Crown Drill to the T-Handle (Fig. 39) and slide it over the K-Wire to the tip of the greater trochanter.

With gentle clockwise turning and pushing movements, the Crown Drill will drill into the proximal part of the trochanter and prepare the canal for the proximal part of the Gamma3 Nail. The Crown Drill stops when the correct depth is reached (Fig. 40 and 41).

## Warning:

If using a power tool to drive the Crown Drill, particular attention must be paid to the position of the K-Wire. The Crown Drill is a front and side cutting instrument and should be used with great care to ensure that the sharp edges of the reamer do not inadvertently ream intact bone.



Fig. 39

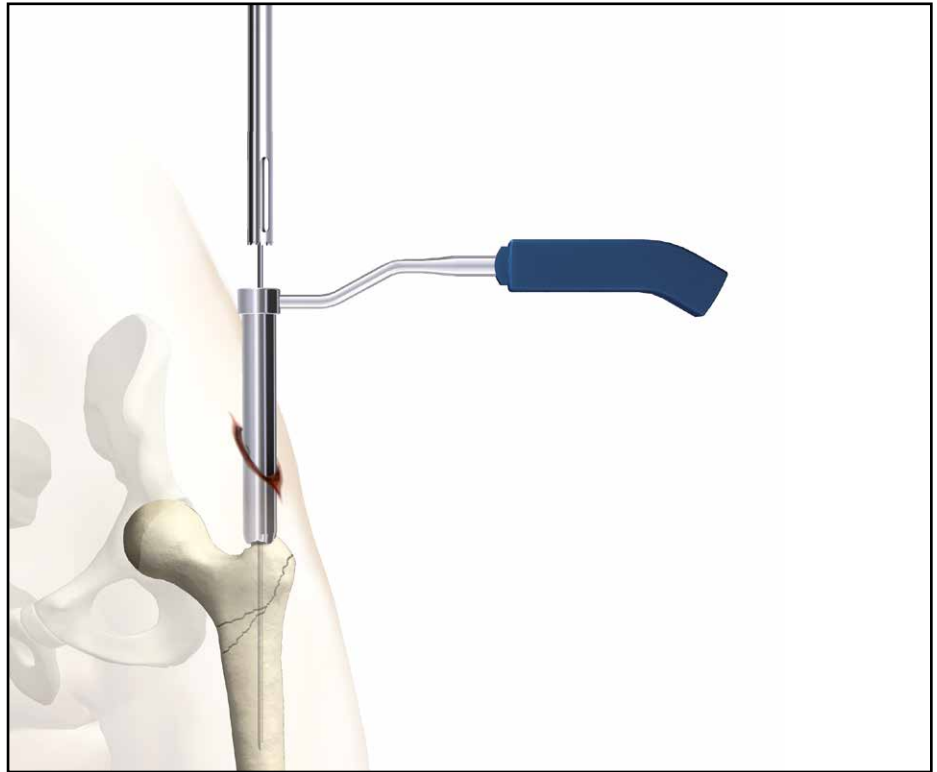


Fig. 40

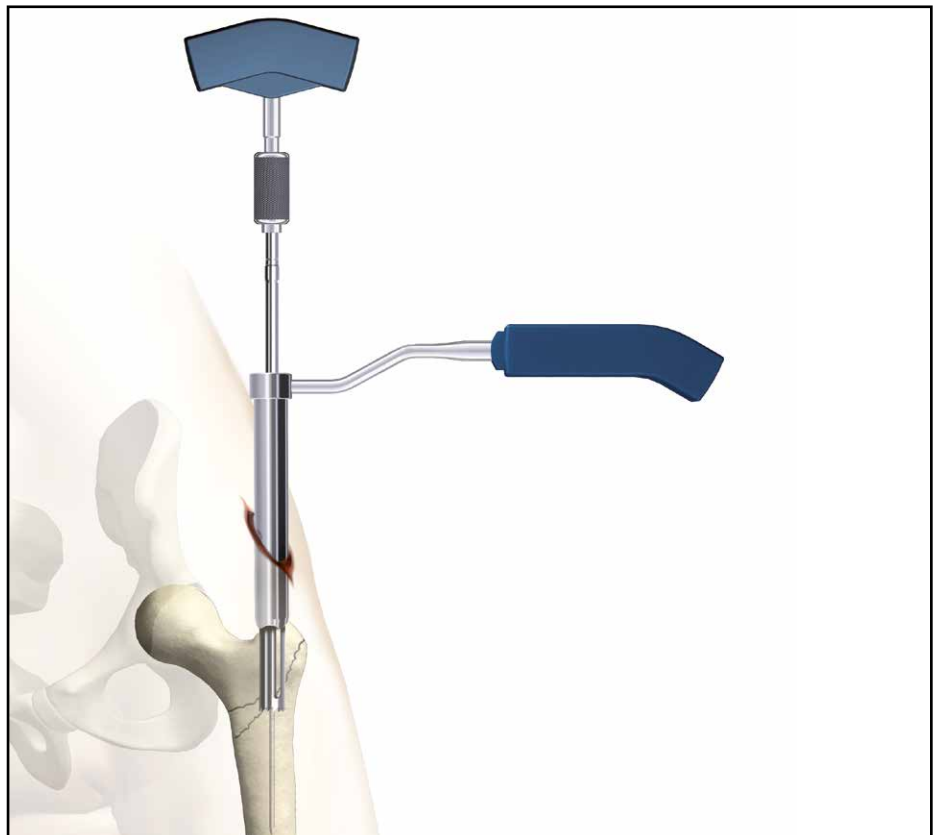

Fig. 41

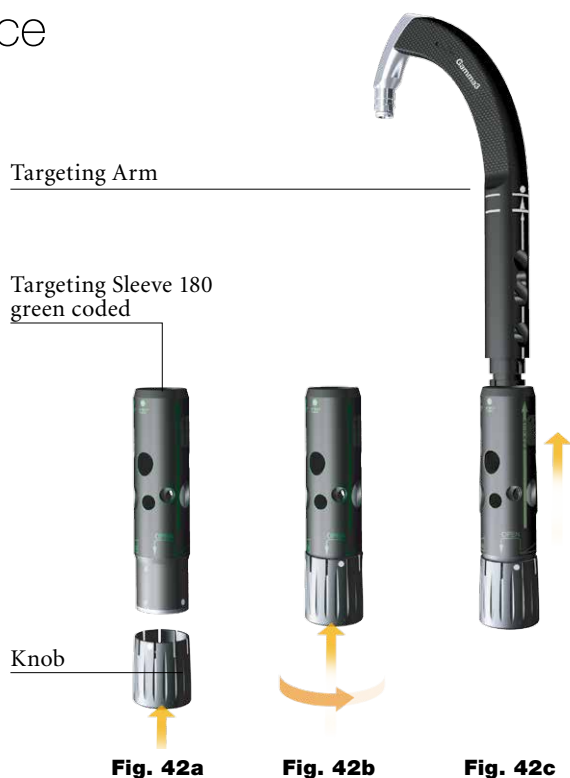# Operative Technique

## Assembly of Targeting Device

### 1. Targeting Sleeve and Knob Assembly

First assemble the Knob to the Targeting Sleeve (Fig. 42a) and adjust the point on the Knob to be in line with the arrow on the Target Sleeve. Push the knob hard against the sleeve. The Knob moves approximately 5mm to the sleeve and has to be turned clock-wise by approximately 30 degrees. Now release the Knob and it will slip back the same distance. Now the Knob is assembled to the Targeting Sleeve and has to be connected to the Target Arm (Fig. 42c).

As an alternative, the Speedlock Sleeve is newly available and allows for assembly of the sleeve directly to the Targeting Arm without going through above mentioned step. The Speedlock Sleeve has the same functions as the assembled Targeting Sleeve and Knob. This Operative Technique describes the use with the Speedlock Sleeve (Fig. 43) in the following chapters.



### 2. Targeting Arm and Speedlock Sleeve Assembly

Push the Speedlock Sleeve assembly over the Targeting Arm along the line until it stops (arrow line to arrow line).

Rotate the Speedlock Sleeve around to the required nail angle position for the Lag Screw, e. g. 125° (point to point) or distal locking positions, either "Dynamic" or "Static". Now the Targeting Sleeve must be fixed in this position by pushing it strongly against the Targeting Arm. You will feel and hear as the sleeve snaps into position.

By turning the Speedlock Sleeve Knob into the "lock" position, the Speedlock Sleeve can be locked to the Targeting Arm. It also locks either the Lag Screw Guide Sleeve or the Tissue Protection Sleeve.



# Operative Technique

## 3. Assembly of the Targeting Device and the Gamma3 Long Nail

The selected Gamma3 Long Nail is now assembled to the Carbon Fibre Targeting Device as shown in Figure 44. The nail connecting part of the Targeting Device is designed with an easy assembly function for fast and secure nail fixation.

Ensure that the locating pegs fit into the corresponding notches of the proximal part of the nail.

**Fully tighten the Nail Holding Screw with the Ball Tip Screwdriver, so that it does not loosen during nail insertion.**

Before starting surgery the following two functions of the Targeting Device have to be checked:

1. Secure fixation between Nail and Targeting Device
2. Lag Screw Guide Sleeve matches the selected nail angle.



**Fig. 44**  
Gamma3 Long Nail Assembly



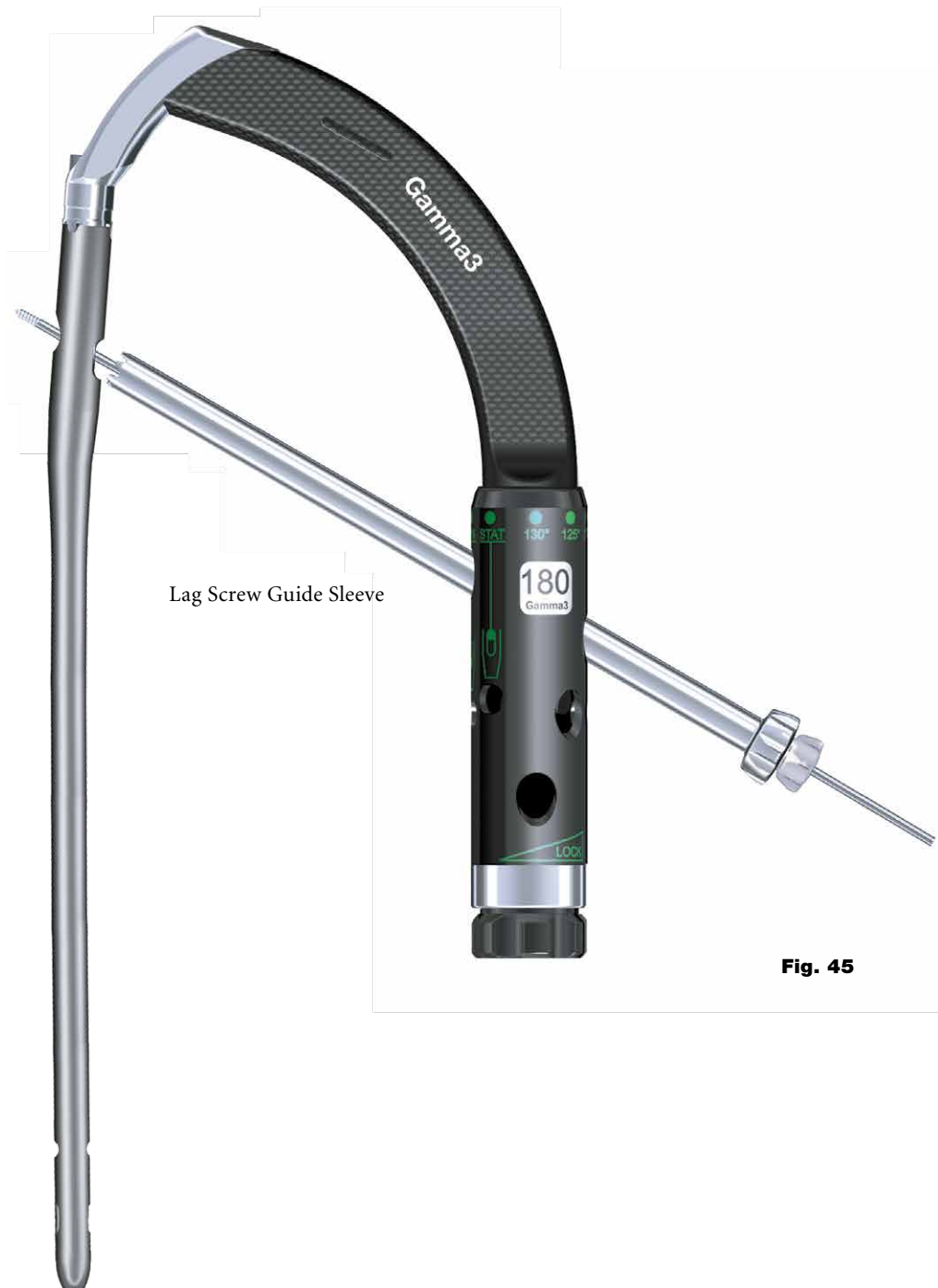# Operative Technique

Before checking the function of the Lag Screw Guide Sleeve, the Speedlock Sleeve Knob must be positioned in the counter clockwise position. Pass the Lag Screw Guide Sleeve gently through the hole of the Speedlock Sleeve and tighten it gently in its final position by turning the Knob clockwise. Check correct nail angle using the K-Wire, 4.2mm Drill or Lag Screw Step Drill (Fig. 44).

Remove the Lag Screw Guide Sleeve in the opposite order; turn the Speedlock Sleeve Knob counter-clockwise and remove the Lag Screw Guide Sleeve by pulling it back.

**Note:**

**Before starting surgery, the implant and instrument assembly must be checked. Ensure that the Sleeve angle matches the corresponding nail angle chosen, e. g. a 125° position in Speedlock Sleeve for a 125° nail (Fig. 45).**



**Fig. 45**

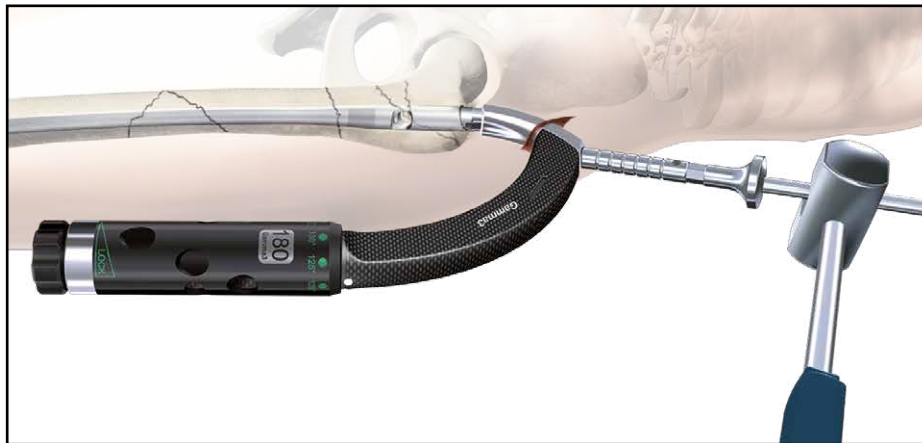
# Operative Technique

## Nail Insertion

The nail is advanced through the entry point passing the fracture site to the appropriate level.

If dense bone is encountered, first re-evaluate that sufficient reaming has been achieved, then, if necessary, the Strike Plate can be attached to the Targeting Arm and the Slotted Hammer may be used to further insert the nail (Fig. 46).

More commonly, the nail is positioned too proximal and correction of the nail should be carried out either by hand or by using the Strike Plate placed into the Target Device. If a higher position is required, the Universal Rod and Slotted Hammer may then be attached to the Strike Plate to carefully and smoothly extract the assembly. The new position is checked again with the image intensifier as described above.



**Fig. 46**

### Caution:

**The nail must progress smoothly, without excessive force. If too much resistance is encountered, removal of the nail and additional reaming is recommended.**

### Note:

**Remove the Guide Wire prior to drilling or K-Wire insertion.**

## Final Seating with Impactor

The carbon fiber guide should never be struck as it may break or become deformed. The impactor that is provided can be utilized to assist with final seating of the nail. Gentle tapping will produce small adjustments (in the nail position) that can help to optimize the ultimate position of the lag screw in the femoral head. The nail holding screw should be re-tightened following any use of the impactor.

The impactor should not be utilized to force the nail down the canal. If the nail cannot be seated manually or if there is no advancement each time the impactor is tapped, A/P and Lateral fluoroscopic X-Rays should be reviewed to determine the cause of the impingement - there may be a mismatch between the nail geometry and the medullary canal. The starting position, the femoral bow and the canal diameter should all be examined to ensure that the leading end of the nail is not impinging on the medial or anterior cortex and that the canal itself has been sufficiently reamed.

Periodically, nail removal and further reaming of the diaphysis may be required.

The proximal metaphyseal flair may be undersized (particularly in young patients or those of short stature) and serve to prevent nail advancement. If this situation is encountered, a flexible reamer may be used to further widen this area to the level of lesser trochanter.

To facilitate manual passage, the nail should be rotated 90° internally until the fracture has been passed.



# Operative Technique

The final Nail depth position is monitored with the image intensifier C-Arm; the projected axis of the Lag Screw may be projected with a ruler on the monitor screen to ensure that the Lag Screw is placed in the optimal position.

Proceed until the axis of the Lag Screw hole (visible as a crescent shape on the screen) is aligned with the lower half of the femoral neck (Fig. 47). The objective of this is to ultimately position the Lag Screw centrally or slightly inferior in femoral head in the frontal plane.



Fig. 47

## Note:

**Remove Guide Wire for the flexible reamer and nail insertion using Guide Wire Handle.**

When the Gamma3 Nail has been inserted to its final depth, check the anteversion of the nail. By using of the K-Wire Clip or Closed Tube Clip with K-Wires (Fig. 48). As an alternative the Gamma3 U-Wire can be used with the K-Wire Clip or Closed Tube Clip. The K-Wire Clip or Closed Tube Clip is mounted into the slots of the Target Arm by pressing the Clip flanges together.

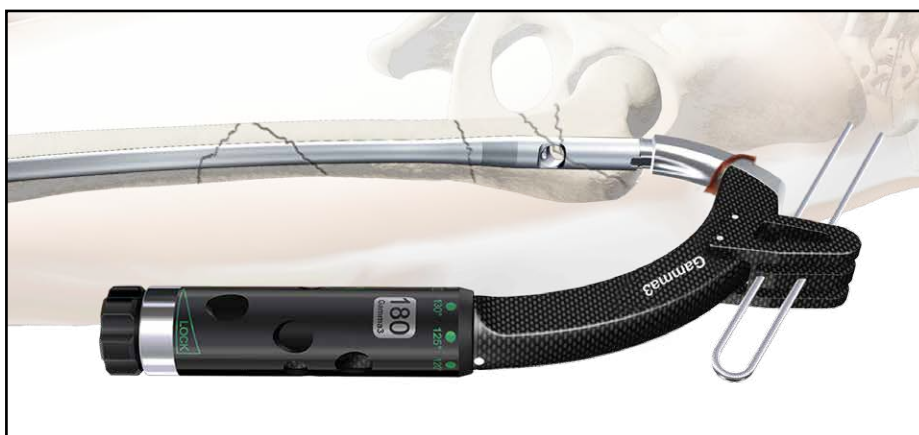

Fig. 48

## Note:

**Before proceeding ensure that the Nail Holding Screw is still fully tightened.**

The Lag Screw should be placed in the central position of the femoral head in the lateral view (Fig. 49).

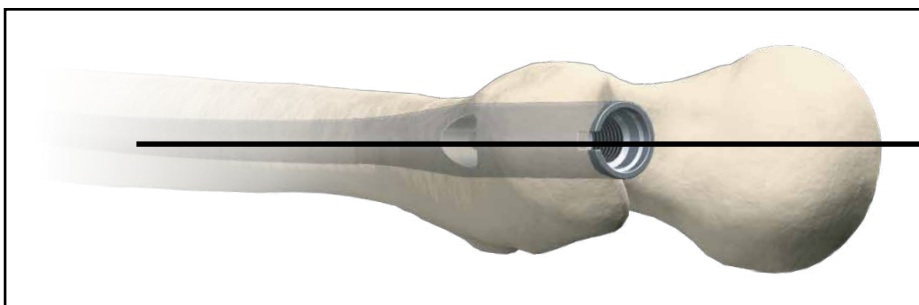
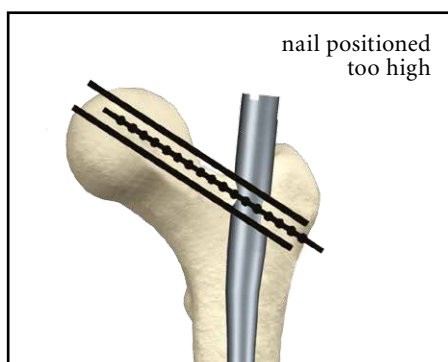
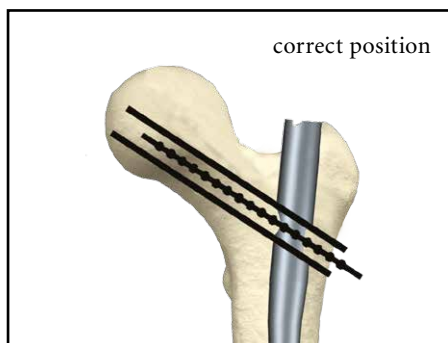
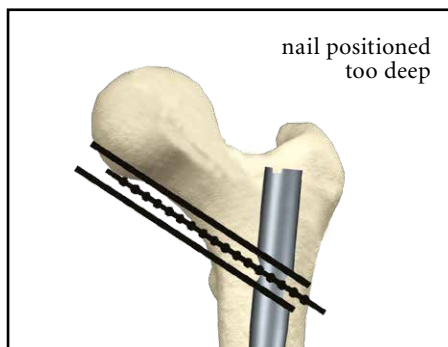


Fig. 49

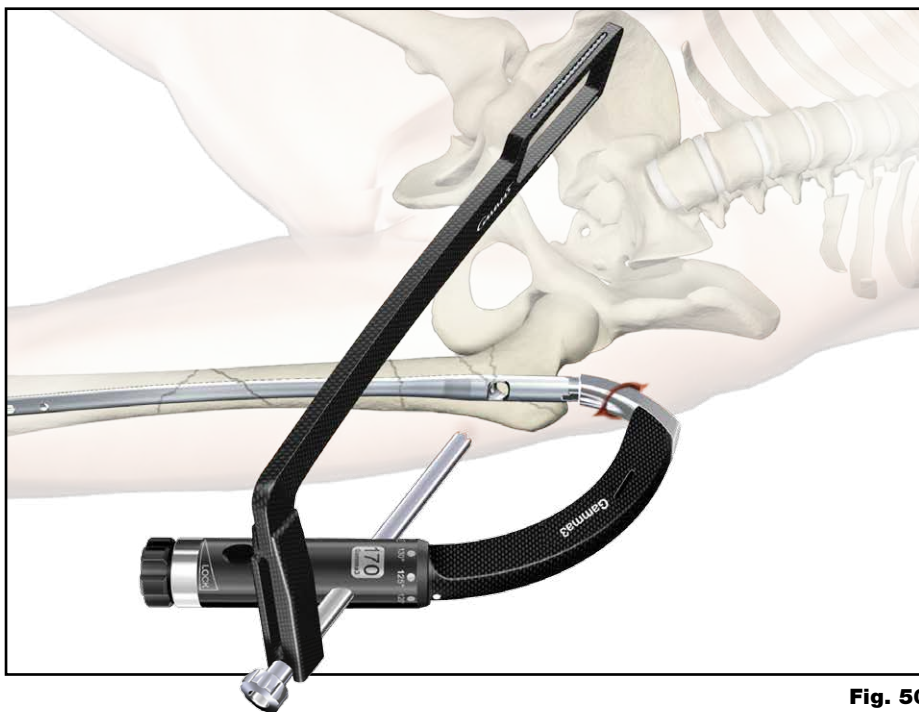
# Operative Technique

## Lag Screw Positioning using the One Shot Device


The One Shot Device is recommended for establishing whether the Lag Screw is in the optimum position. This device is designed to enable correct positioning of the K-Wire for Lag Screw placement before performing lateral skin incision and opening of the lateral cortex (see Fig. 50–51a).



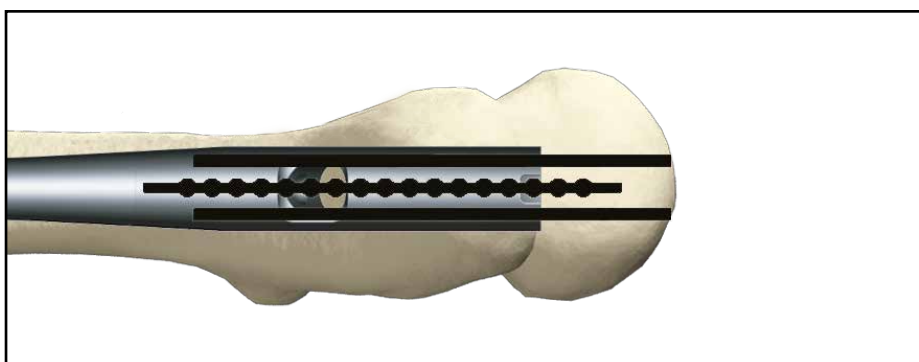
**Fig. 50a-c**  
A/P view



**Fig. 50**  
Positioning of nail depth



**Fig. 51**  
Positioning of anteversion



**Fig. 51a**  
Lateral view

# Operative Technique

## Lag Screw Insertion

The Targeting Device may be held by an assistant to prevent its weight from externally rotating the nail until the next stage is completed.

Next, assemble the Lag Screw Guide Sleeve with the green coded 4.2mm Lag Screw Drill Guide Sleeve and pass them through the Targeting Sleeve to the level of the skin. This indicates the position for a small incision down to the bone (Fig. 52). The Guide Sleeve assembly is now advanced through the incision. If the guide catches the fascia lata, twisting it will usually allow it to pass through to the bone.

In order to facilitate the smooth insertion of the sleeve assembly, the Paddle Tip Trocar can optionally be used prior to the use of the Lag Screw Drill Guide Sleeve. Assemble the Lag Screw Guide Sleeve with the Paddle Tip Trocar and pass them through the Targeting Sleeve to the level of the skin. Make the skin incision down to the bone (Fig 52a). When the tip of the Paddle Trocar catches the fascia lata, twist it manually. There is a mark at the head of the Paddle Tip Trocar that provides the direction of the Trocar Tip. When the tip reaches the bone, replace the Paddle Tip Trocar to the green coded 4.2mm Lag Screw Guide Sleeve and prepare for the next pre-drilling step.

For an accurate Lag Screw length measurement, the outer Guide Sleeve must be in good contact to the lateral cortex of the femur. The Knob of the Target Sleeve must be turned gently **clockwise** to lock the Guide Sleeve in place and further stabilize the targeting assembly (Fig. 53 and 53a).

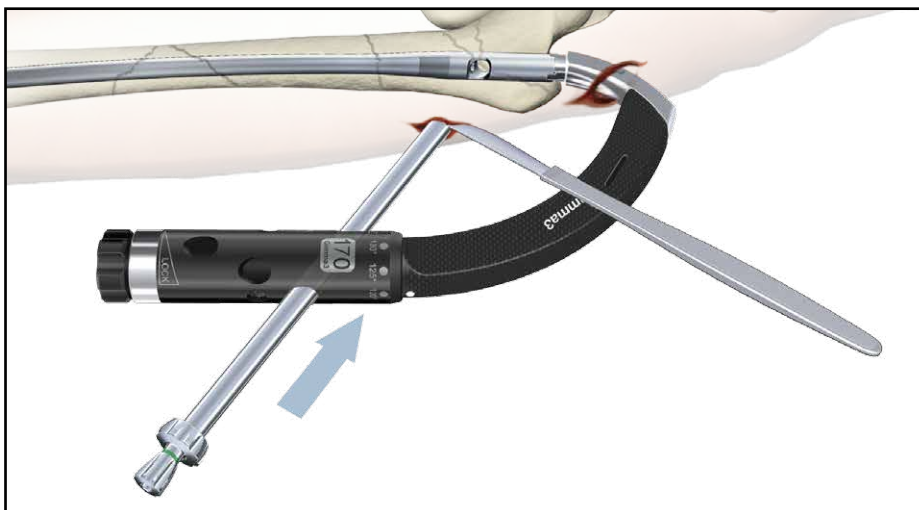


Fig. 52

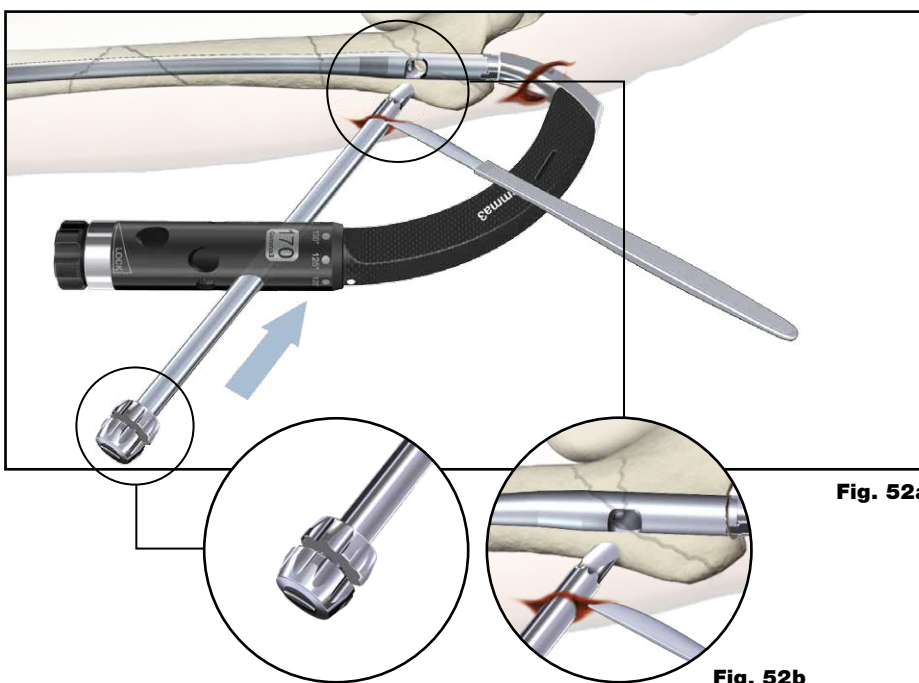


Fig. 52a

Fig. 52b

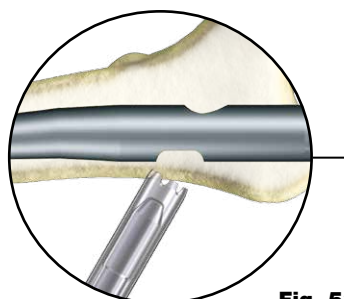


Fig. 53a

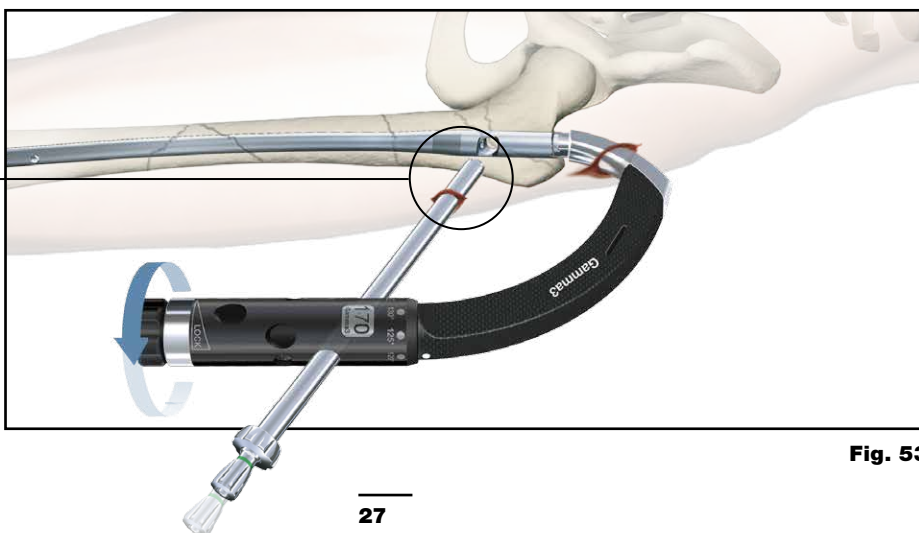


Fig. 53



# Operative Technique

## Pre-Drilling the lateral cortex

With the Lag Screw Guide Sleeve firmly engaged in the cortex, the green coded 4.2mm Lag Screw Drill Guide Sleeve should be pushed gently against the cortex. Using the green coded 4.2mm × 300mm center tipped drill, the lateral cortex should be opened by power tool or by hand. A longer 4.2mm × 360mm drill is also available as an alternative for deeper pre-drilling possibility, allowing for a longer guidance for the K-Wire (Fig. 45).

The green coded 4.2mm Lag Screw Drill Guide Sleeve is then replaced by the K-Wire Sleeve. (Both sleeves look similar, but have different inner hole diameters. The K-Wire Sleeve has no colored ring).

### Note:

**Before proceeding, check that the Guide Wire for the flexible reamer and nail insertion used earlier has been removed.**

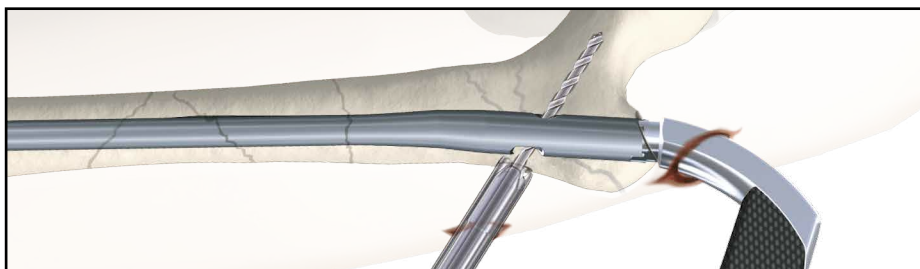
The single use K-Wire inserted through the K-Wire Sleeve should be advanced up to the subchondral bone (Fig. 46), using the Guide Wire Handle or using power tool. Check that the K-Wire is placed either central or in the lower half of the femoral head in the frontal plane and on the midline in the lateral plane (Fig. 46a).

### Note:

**Pre-drilling offers a possibility to open the lateral cortex for the K-Wire entry. Pre-drilling helps to prevent a possible slipping of the K-Wire on the cortex and may avoid deflection within the femoral head. This helps to perform the Lag Screw reaming without nail contact. Therefore check the proper K-Wire position with the image intensifier in both the anterior-posterior and mediolateral views as shown in Fig. 38 and 40 to ensure that K-Wire deflection did not occur.**

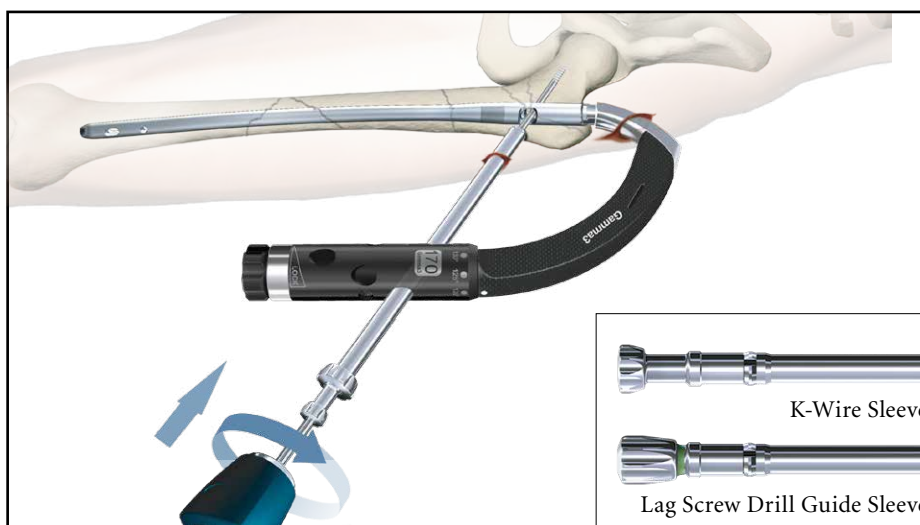
### Warning:

**In the event the nail is damaged during Lag Screw reaming, the fatigue strength of the implant may be reduced, which may cause nail to fracture.**



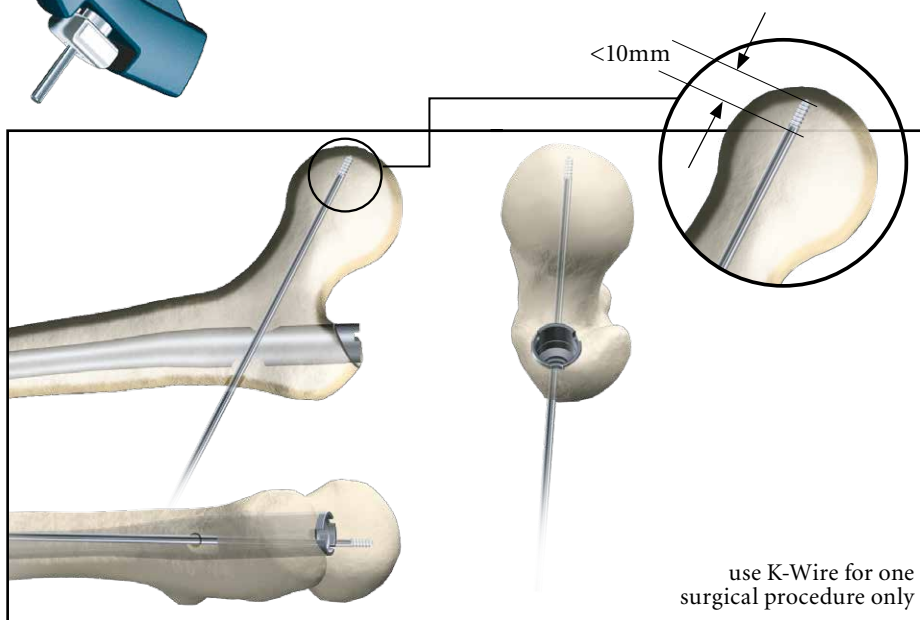
**Fig. 54**

Opening of the lateral cortex



**Fig. 55**

K-Wire placement



**Fig. 55a**

K-Wire placement

# Operative Technique

## Lag Screw Insertion

The objective is to position the Lag Screw below the center of the femoral head in the anterior-posterior view and centrally in the lateral view, to provide the best load transfer to the Lag Screw.

After satisfactorily positioning the K-Wire, the required Lag Screw length is measured using the Lag Screw Ruler.

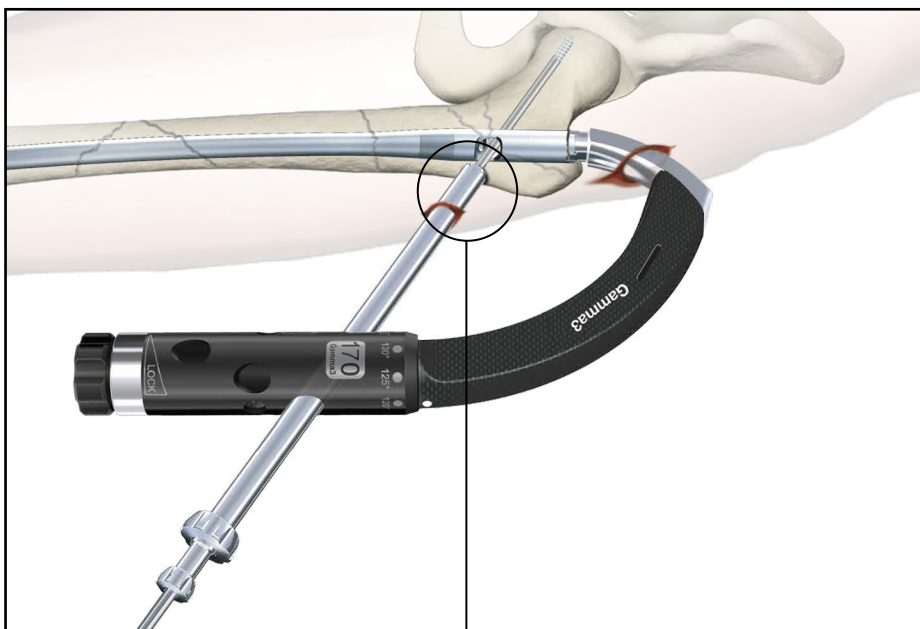
Before starting to measure, ensure that the Lag Screw Guide Sleeve is still pressed firmly against the lateral cortex of the femur (Fig. 56).

Place the Lag Screw Ruler directly under the K-Wire (Fig. 57).

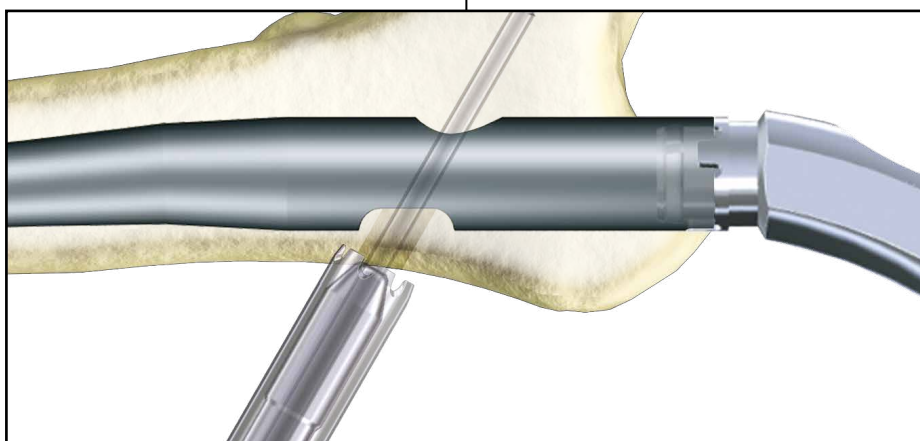
The recommended value for the Step Drill depth and the Lag Screw length can be read directly off the Lag Screw Ruler. If the value is between markings on the scale, e.g. 97mm, it should always be rounded up to the next higher value, e.g. 100mm.

### Note:

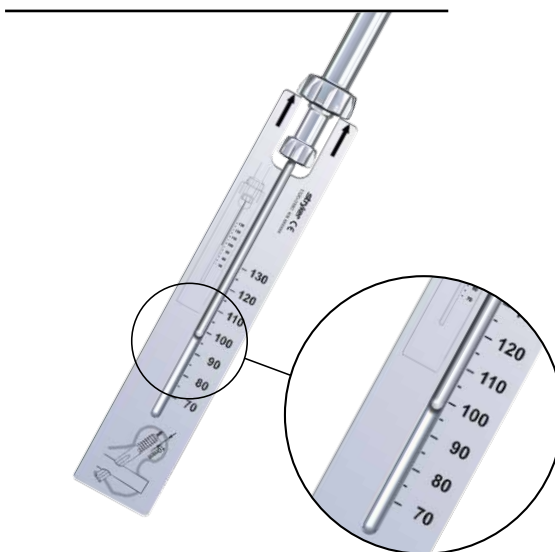
**K-Wires are not intended for re-use. They are single use only. K-Wires may be damaged or bent during surgical procedures. If a K-Wire is re-used, it may get lodged in the drill and could be advanced into the pelvis during the following steps of the procedure. This may damage large blood vessels or cause other serious injuries.**



**Fig. 56**  
Lag Screw length measurement



**Fig. 56a**



**Fig. 57**  
Lag Screw Length Measurement

# Operative Technique



**Fig. 58**

The value of the measurement (Fig. 58) is now transferred to the adjustable stop on the Lag Screw Step Drill.

The value e. g. 100 must be visible in the window of the Step Drill Stop (Fig. 58a).

The K-Wire Sleeve is now removed and the adjusted Lag Screw Step Drill is passed over the K-Wire (Fig. 54), through the Lag Screw Guide Sleeve.

The channel for the Lag Screw is prepared using the T-handle connected to the Lag Screw Step Drill. If exceptional resistance is encountered, a power drill may be used with great care.

Drilling should continue until the stop of the Step Drill comes into contact with the Lag Screw Guide Sleeve (Fig. 59 and 60). Ensure that the Targeting Device is well supported to prevent it from slipping back or rotating.


The drilling process, especially when the tip of the drill comes close to its final position in the femoral head, should be controlled under an image intensifier to avoid hip joint penetration. The K-Wire can also be observed in the K-Wire window of the Step Drill.

## Note:

It is important to observe the K-Wire tip during drilling on the intensifier. The K-Wire window provides an additional possibility to double check the K-Wire end position.

## Warning:

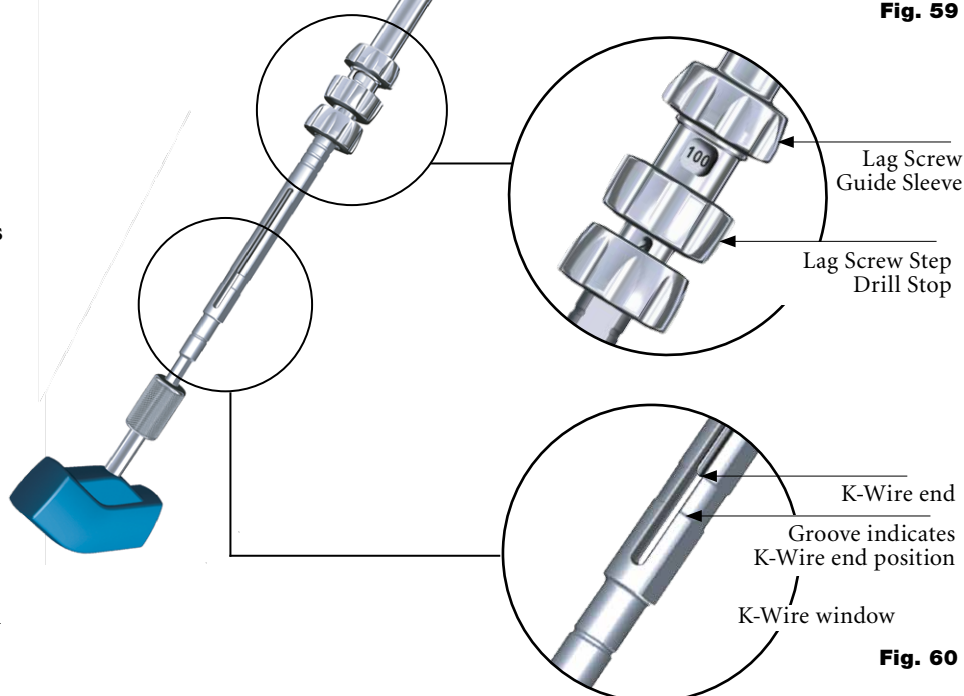
Ensure that under no circumstances the K-Wire is advanced into the pelvis. In case a deflection of the K-Wire is observed, it is strongly recommended to remove the K-Wire and replace it by a new one. If the Stepdrill does not pass through the Lag Screw hole with ease, check by image intensifier whether the K-Wire is deflected or not. Never drive the Stepdrill with force through the nail, since this may cause severe damage to the nail resulting in the increase risk of the implant failure.



**Fig. 58a**



**Fig. 59**



**Fig. 60**

# Operative Technique

## Lag Screw Insertion

Check on the image intensifier during drilling to monitor the depth of the drill near the subchondral bone.

At this stage, you should see the tip of the K-Wire protruding about 6 to 10mm out of the step drill. This is because the threaded portion of the K-Wire was intentionally not included in the drill measurement. This is to prevent the drill from penetrating the joint (Fig. 61) and to ensure that the K-Wire remains anchored in the subchondral bone after reaming. Remove the Step Drill by turning it clockwise and pulling it backwards.

In case of the hard bone, the Lag Screw Tap is available as an option.

Transfer the value of the measurement (Fig. 48) to the adjustable stop on the Lag Screw Tap (Fig. 62a). Make sure that the value (e. g. 100) is visible in the window (Fig. 62b). The selected length of the Step Drill, the Lag Screw Tap and the Lag Screw should all be the same (in this example 100mm).

The screw is then assembled to the Lag Screwdriver (Fig. 63).

In a case where compression is to be applied, a shorter Lag Screw length should be chosen to avoid the excessive lateral Lag Screw protrusion (see chapter Compression/ Apposition below). Ensure that the pins of the Lag Screwdriver are in the slots of the Lag Screw. The end thumbwheel must be turned clockwise and tightened using the Ball Tip Screwdriver.

The Lag Screw assembly is now passed over the K-Wire, through the Lag Screw Guide Sleeve, and threaded up to the end of the pre-drilled hole of the femur head. Check the end position of the Lag Screw on the image intensifier. A double check of the end position is also possible with the indicator ring (Fig. 63a) on the Lag Screw Screwdriver when it reaches the end of the Lag Screw Guide Sleeve.

### Warning:

**Make sure that the K-Wire does not protrude into the pelvis during the Lag Screw insertion.**

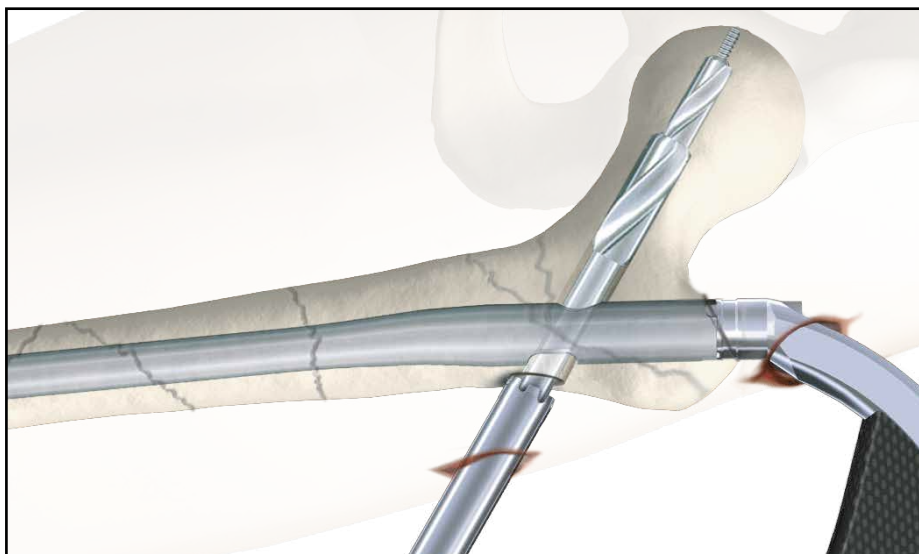


Fig. 61



Fig. 62a

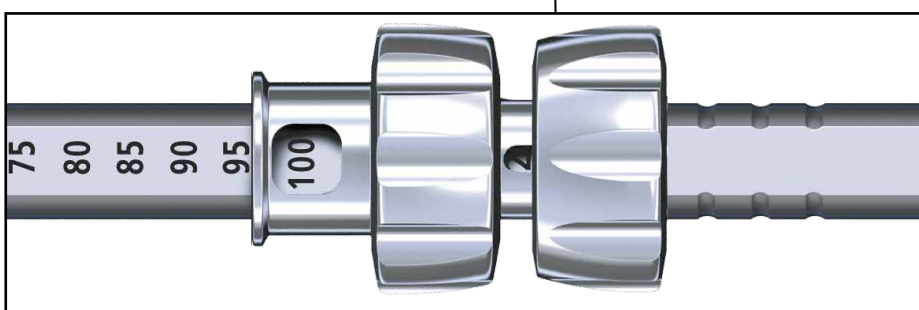


Fig. 62b




Fig. 63

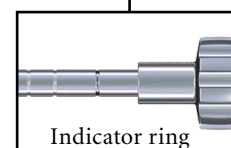


Fig. 63a



# Operative Technique

## Lag Screw Fixation

The handle of the Lag Screwdriver must be either parallel or perpendicular (90°) to the Targeting Arm (Fig. 65 on next page) to ensure that the Set Screw is able to fit into one of the four grooves of the Lag Screw shaft.

**The Set Screw alignment indicator will help to find the right position of the handle.**

If the T-handle is not perpendicular or parallel to the Targeting Arm, turn it clockwise until it reaches this position. NEVER TURN THE LAG SCREW COUNTER CLOCKWISE.

If the K-Wire is inadvertently removed, the screw may still be inserted without it, provided that the Guide Sleeve is still in contact with the cortex.

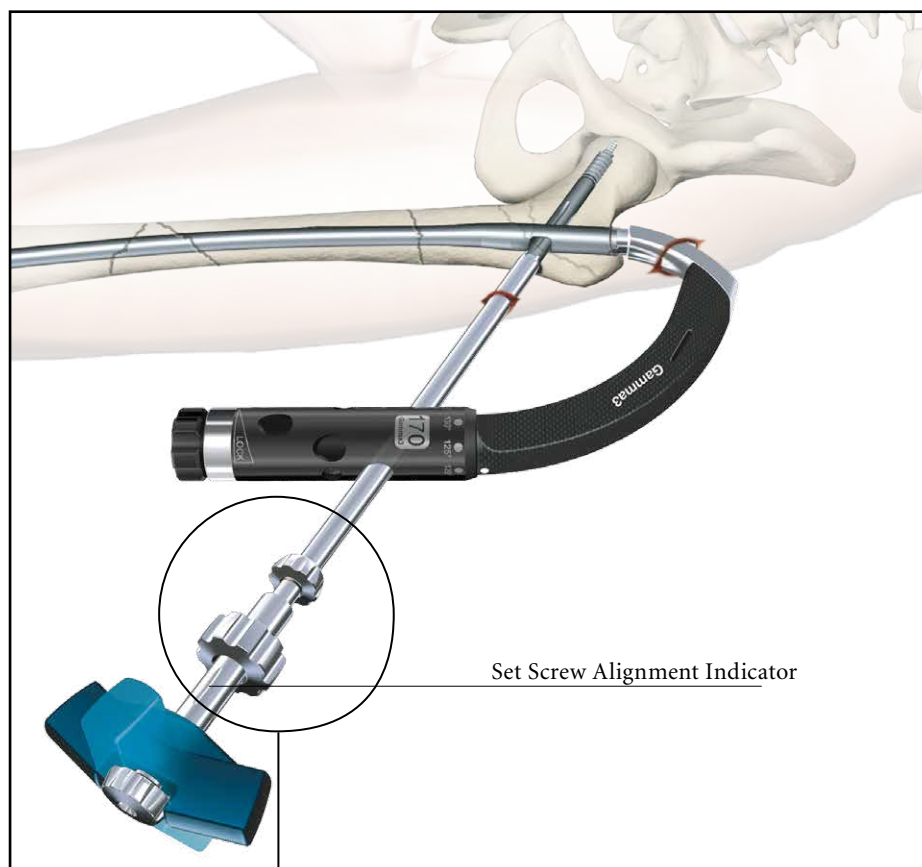
### Warning:

**It is strongly recommended to place the Lag Screw at the end of pre-drilled hole in order to provide maximal resistance against cut-out. Never turn the Lag Screw counter-clockwise after the final position is reached, because otherwise the Lag Screw may lose full bony surface contact to its tip.**


### Compression/ Apposition

If compression or apposition of the fracture gap is required, this can be achieved by gently turning the thumb-wheel of the Lag Screwdriver clockwise against the Guide Sleeve (Fig. 64). Before starting compression, make sure that the Lag Screw Guide Sleeve is unlocked to allow its free sliding. To unlock the Lag Screw Guide Sleeve, the Knob of the Target Device has to be turned counter clock-wise.

In osteoporotic bone care must be taken to prevent Lag Screw pullout in the femoral head. The Lag Screw should be chosen shorter depending on the expected amount of compression.



**Fig. 64**





# Operative Technique

## Set Screw Insertion

### Note:

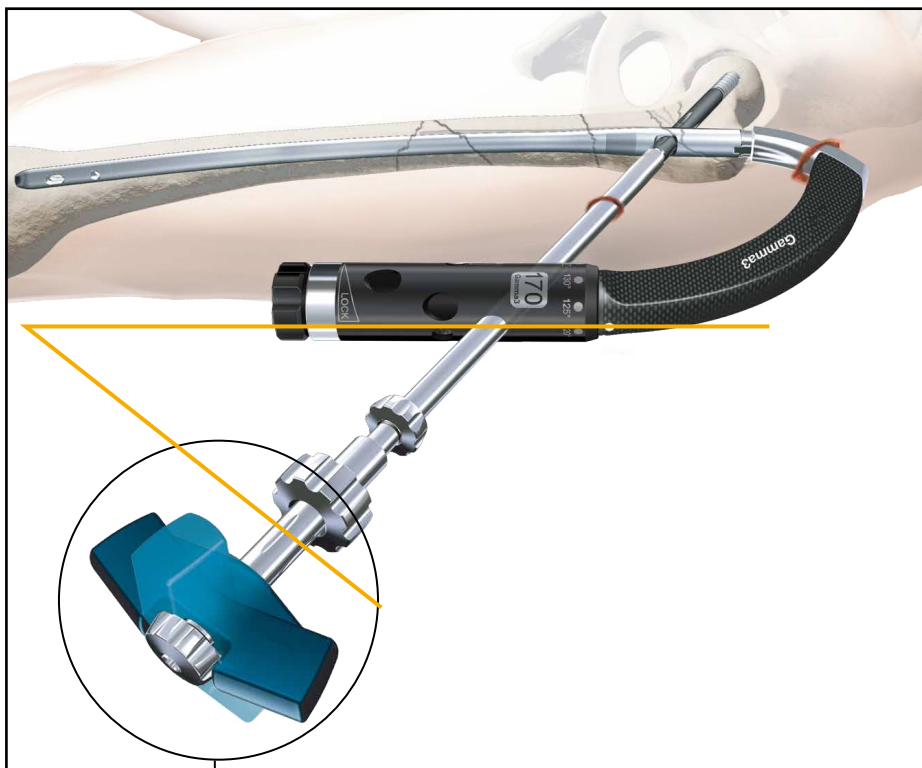
**The Set Screw must be used.  
The use of the Set Screw is not an option.**

Assemble the Set Screw to the Set Screw Driver. Insert the Set Screw as shown in Figure 66 along the opening of the post of the Targeting Device and advance it through the Nail Holding Screw pushing the Set Screwdriver.

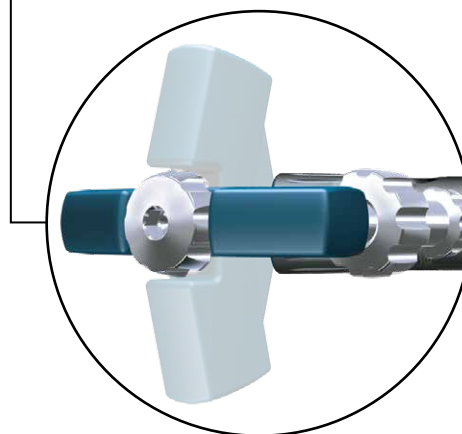
**Push the Set Screw Driver down until you are sure that the Set Screw engages the corresponding thread in the nail. While pushing down the assembly, you may feel a slight resistance.**

Turn the Screwdriver handle clockwise under continuous pressure. You may notice a resistance when turning the Set Screw. This is because the Set Screw thread is equipped with the “Nylstop” system to prevent spontaneous loosening.

This is not the final position for the Set Screw. Keep on turning the Set Screw until you feel contact in one of the grooves of the Lag Screw.



**Fig. 65**  
T-Handle end position



**Fig. 65a**

# Operative Technique

## Lag Screw Fixation

To verify the correct position of the Set Screw, try to turn the Lag Screwdriver gently clockwise and counterclockwise. If it is not possible to turn the Lag Screwdriver, the Set Screw is engaged in one of the grooves. If the Lag Screw Driver still moves, reposition the handle position and tighten the Set Screw again until it engages in one of the four grooves.

After slightly tightening the Set Screw it should then be unscrewed by one quarter ( $\frac{1}{4}$ ) of a turn, until a small play can be felt at the Lag Screwdriver. This ensures a free sliding of the Lag Screw.

Make sure that the Set Screw is still engaged in the groove by checking that it is still not possible to turn the Lag Screw with the Lag Screwdriver.

### Note:


**Do not unscrew the Set Screw more than  $\frac{1}{4}$  of a turn.**

As an alternative, the Set Screw can be inserted using Gamma3 Closed Tube Clip (see next page).

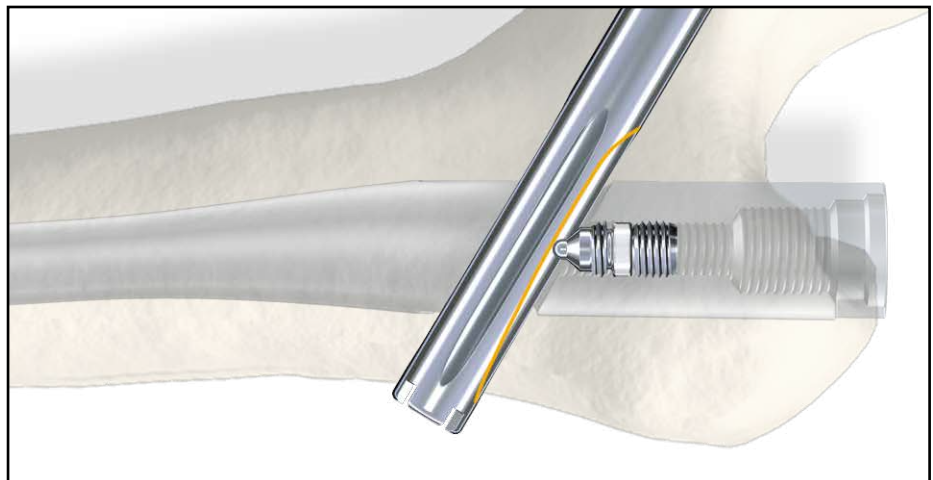
If distal locking is not indicated, the End Cap should be assembled to the nail end to prevent bone ingrowth. Leaving the Lag Screwdriver in place, the Nail Holding Screw is now removed using the ball tip Screw Driver or Universal Socket Wrench and turning it counter clockwise. Insert the End Cap (size 0) using the Socket Wrench or the Ball Tip Screwdriver. The End Cap should be tightened slightly.

Please see chapter “End Cap Insertion”.

Alternatively the End Cap could also be inserted free hand after removal of the Target Device.



**Fig. 66**



**Fig. 67**  
Set Screw insertion

# Operative Technique

## Alternative:

### Set Screw Insertion with Gamma3 Closed Tube Clip

Taking the Gamma3 Closed Tube Clip and clipping it onto the Gamma3 Targeting Arm, it is possible to create a guided path for the Set Screwdriver. With this new feature, by pushing down the flexible Set Screwdriver into the nail axis, the Set Screw can be easily guided into the cannulation of the nail. It is possible to assemble the Closed Tube Clip either prior to the Nail insertion or prior to the Set Screw insertion as shown in Fig. 68a.

#### Step 1

Assemble the Gamma3 Closed Tube Clip to the Targeting Arm by pressing the grip together and releasing it. At this stage, you should assemble it slightly behind the groove of the Targeting Arm (Fig. 68a).

#### Step 2 and Step 3

Hold the Targeting Device and Closed Tube Clip together, then push Closed Tube Clip with your thumb in the direction shown by the arrow until it clicks onto the final position (Fig 68b and 58c).

#### Step 4

Insert the Set Screw according to the normal procedure (Fig. 68d).

#### Caution:

The Gamma3 Closed Tube Clip is designed for the Flexible Set Screwdriver (1320-0233) only and NOT for the Straight Screw Driver (1320-0210) or (1320-0230).

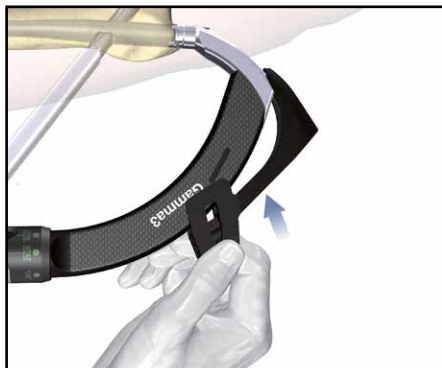


Fig. 68a

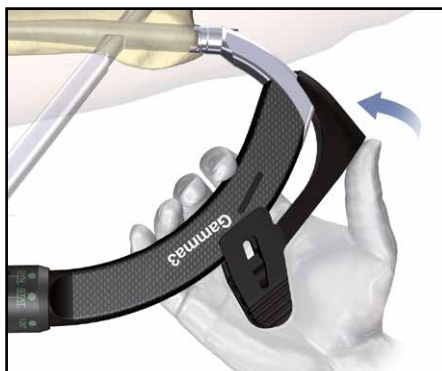

Fig. 68b



Fig. 68c

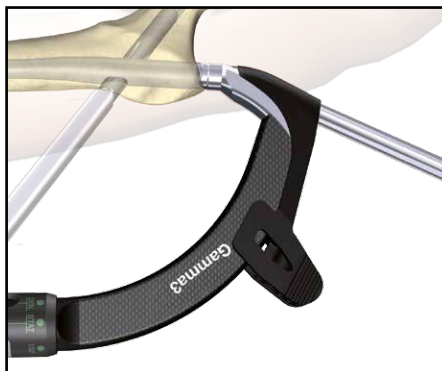

Fig. 68d

# Operative Technique

## Distal Screw Locking

Gamma3 Long Nails offer the possibility to be locked distally. For distal locking, the Long Nail offers the following three locking options (Fig. 69), depending on the fracture pattern.

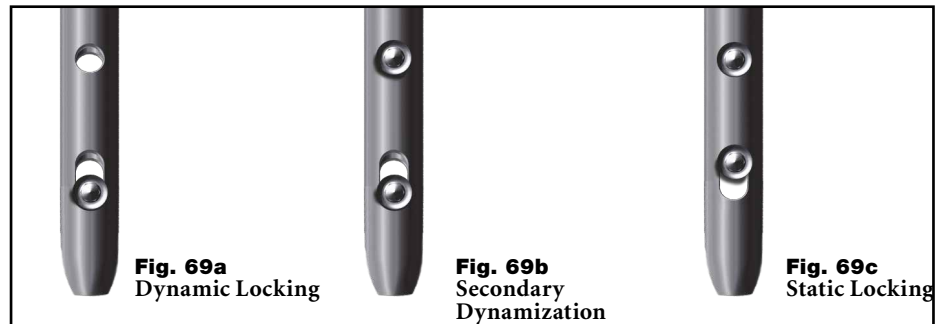
### Long Nail Distal Locking Options

- Locking in the distal part of the oblong hole creates a dynamic locking mechanism – requires only one screw (see Fig. 69a).
- One screw placed in the distal part of the oblong hole and the other in the round hole. If dynamization is required after a period of time, the screw, placed in the round hole, has to be removed – requires two screws (see Fig. 69b).
- One screw placed in the round hole and the other is placed in the proximal part of the oblong hole – requires two screws (see Fig. 69c).

### Distal locking is recommended:

- if the fracture is unstable
- if rotational stability is required
- if there is a wide disparity between the diameter of the nail and the femoral cavity.

Various techniques can be used to guide drilling and insertion of screws through the distal holes. The free-hand technique is described below.

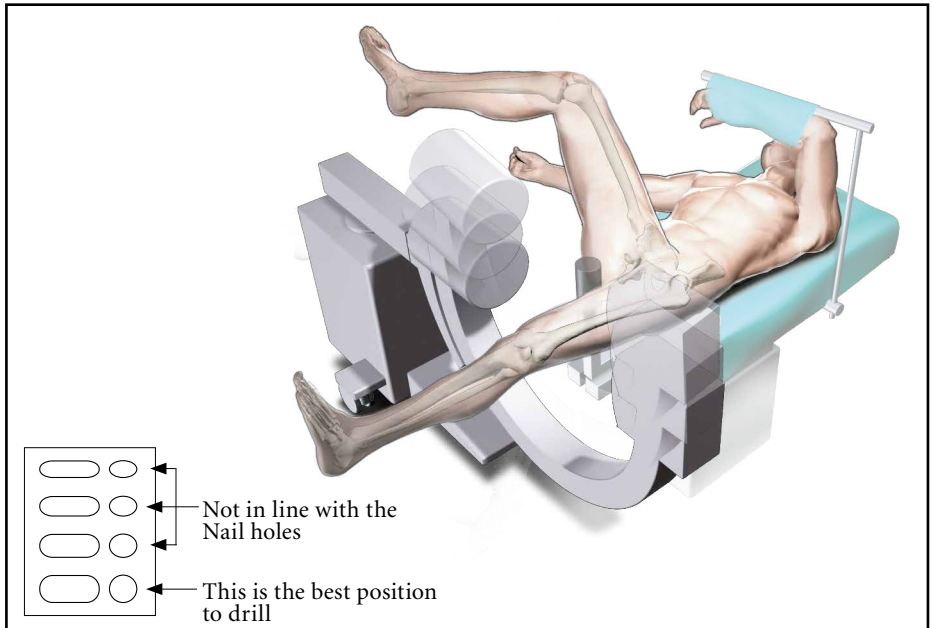


**Fig. 69**

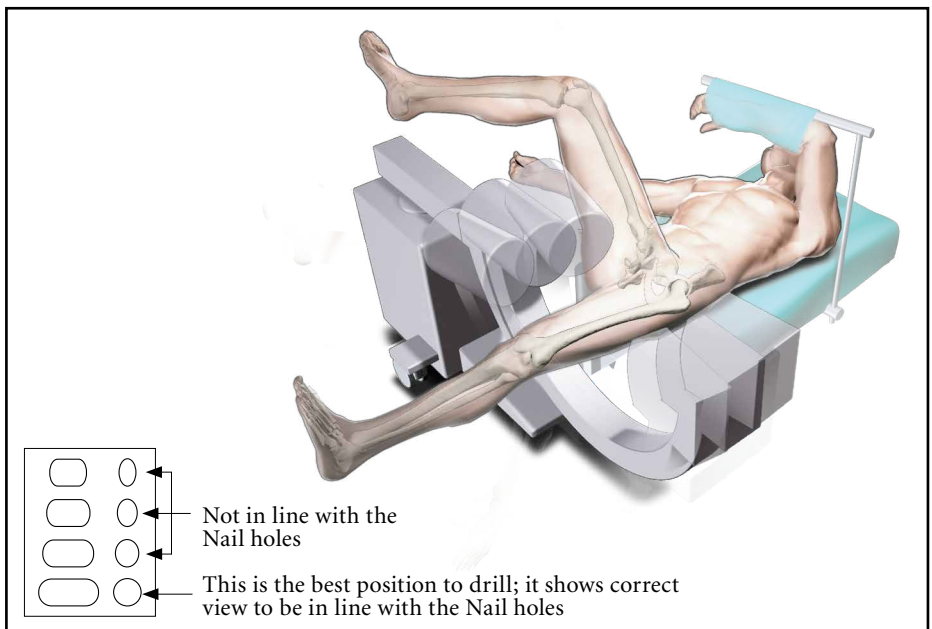
# Operative Technique

## Visualizing the distal holes

The essential initial step in distal targeting is to position the image intensifier so that the distal hole in the nail appears perfectly round. Naturally, this visualization steps refer to the appearance of the round and not the oblong hole. If the hole appears to be elliptical in either the vertical or horizontal plane, the image intensifier position must be adjusted appropriately as shown in Figures 70 and 71. It is advised to correct image in one plane at a time.



**Fig. 70**



**Fig. 71**

# Operative Technique

## Free-hand Technique

The free-hand drill technique is used to fix the distal bone fragment to the nail using Locking Screws. Length and rotational alignment of the leg must be checked before locking the nail. The distal nail locking is described as follows, using the Static Locking mode according to Figures 72-70. Skin incisions are made in line with the distal holes of the nail.

Once the image intensifier is correctly positioned as shown in Figures 64 and 65, use the centre tipped Ø4.2mm x 180mm, green coded drill and place the tip of the drill at an oblique angle to the centre of the hole (Fig. 72). Verify the position by X-ray and move the drill into the same plane as the holes in the nail, then drill through the first cortex and the nail until resistance of the second cortex is felt as shown in Figure 73.

Alternatively, the drill can be drilled through the second cortex while viewing the image intensifier. The screw length can then be read directly from the Screw Scale on the drill (Fig. 74).

If the Tissue Protection Sleeve is used with the drill, it has to be removed for the measurement.

It is also possible to measure the correct screw length using the Free Hand Screw Gauge (Fig. 75). After drilling through the second cortex, remove the drill and advance the small hook of the Screw Gauge through the holes behind the medial cortex and read out the required locking screw length.

Insert the 5mm distal Locking Screw through the skin by using the 3.5mm Screwdriver; advance the screw head carefully until it is just in direct contact with the cortex (Fig. 76).

### Note:

**Take care not to overtighten. The screw head should just come into contact with the cortex and resistance should be felt.**

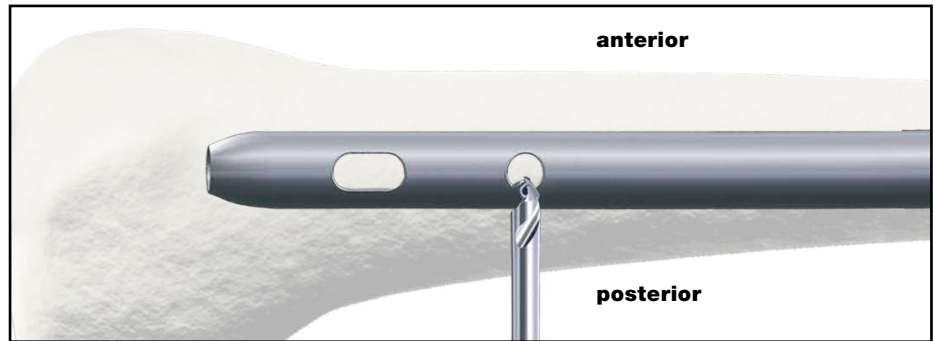


Fig. 72

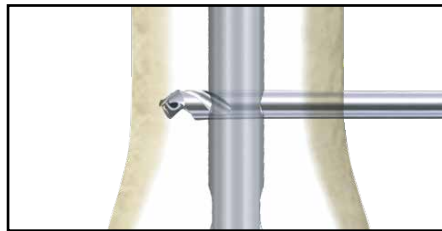


Fig. 73

add thickness of the cortex  
(approx +5mm) to the read out value

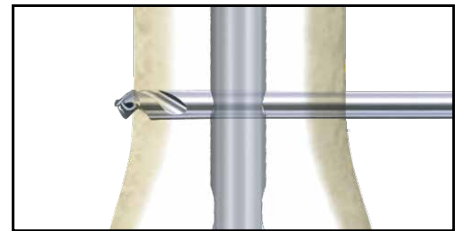


Fig. 74

direct read out

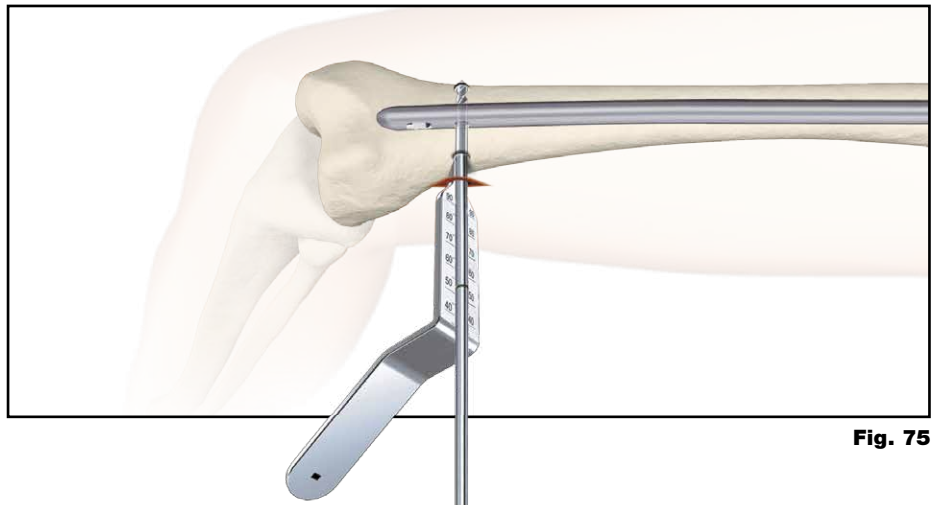


Fig. 75




Fig. 76



# Operative Technique

## Alternative

Alternatively Condyle Screws could be used for distal locking. If a Condyle Screw will be inserted, both cortices are drilled to a diameter of 5mm using the Ø5×230mm Drill in a free-hand drill technique.

After drilling through the second cortex, remove the drill and advance the small hook of the Screw Gauge through the holes behind the medial cortex and read out the required condyle screw length (see Fig. 77).

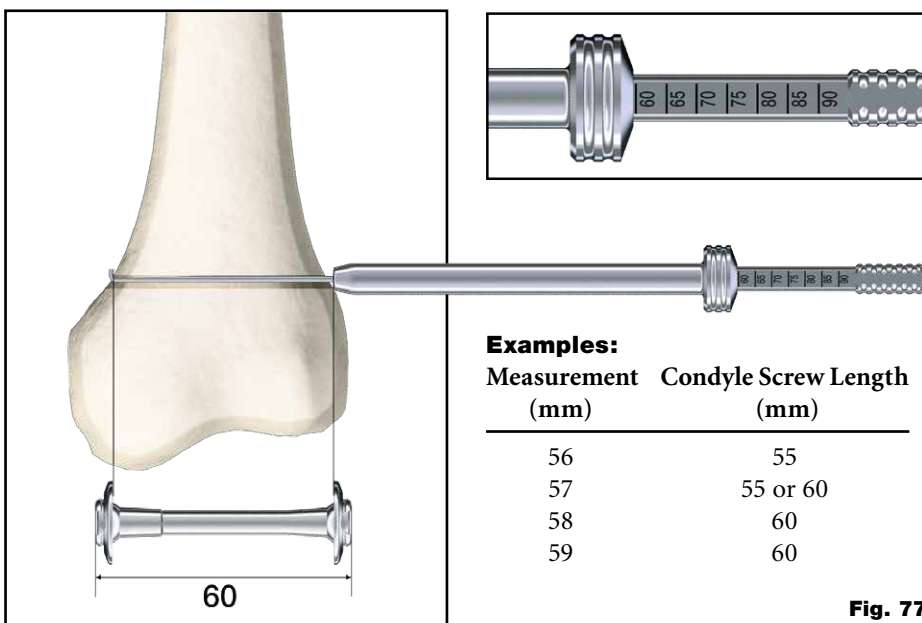
### Note:

**The measurement equals Condyle Screw fixation length (from top of the Condyle Screw head to the top of Condyle Nut head, as shown in Fig. 71). The Condyle Screw length is defined with the Condyle Screw tip flush to the Condyle Nut head. The possible fixation length can be 2mm longer than the Condyle Screw length or 5mm shorter. Please ensure that the Condyle Nut is tightened a minimum of 5 turns on the Condyle Screw!**

The Condyle Screw K-Wire Ø1.8×310mm is inserted from the lateral side to the medial side. At the medial point of the perforation, a skin incision is made for the Condyle Screw. From the medial side, the Condyle Screw is now brought forward over the Condyle Screw K-Wire and inserted using the Condyle Screw Screwdriver. Insert the Condyle Nut over the K-Wire using the other Condyle Screw Screwdriver (Fig. 78 - 79).

Alternatively, if patient anatomy allows, the Condyle Screw may be introduced from lateral to medial in a similar manner as described above.

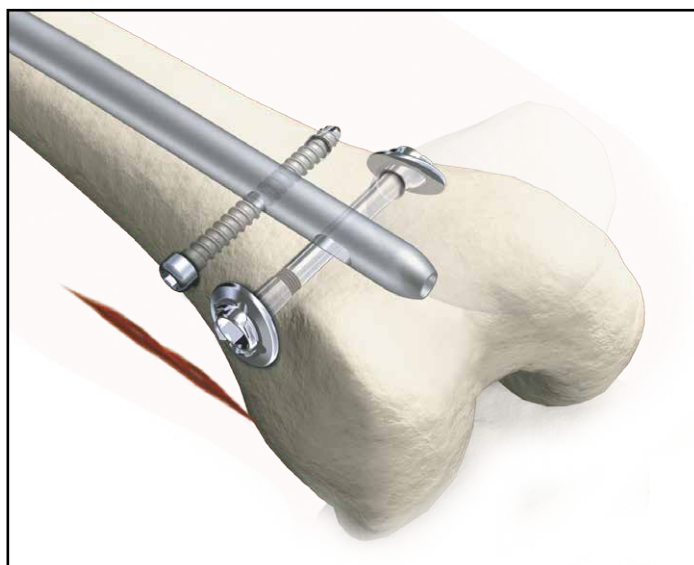
Using both Condyle Screw Screwdrivers, the Condyle Nut and the Condyle Screw are tightened. Once tightened, the K-Wire is removed. The adjustable screw washers of the Condyle Screw and the Condyle Nut adapt to the surface of the bone.



**Fig. 77**



**Fig. 78**



**Fig. 79**  
Final Nail assembly

# Operative Technique

## End Cap Insertion

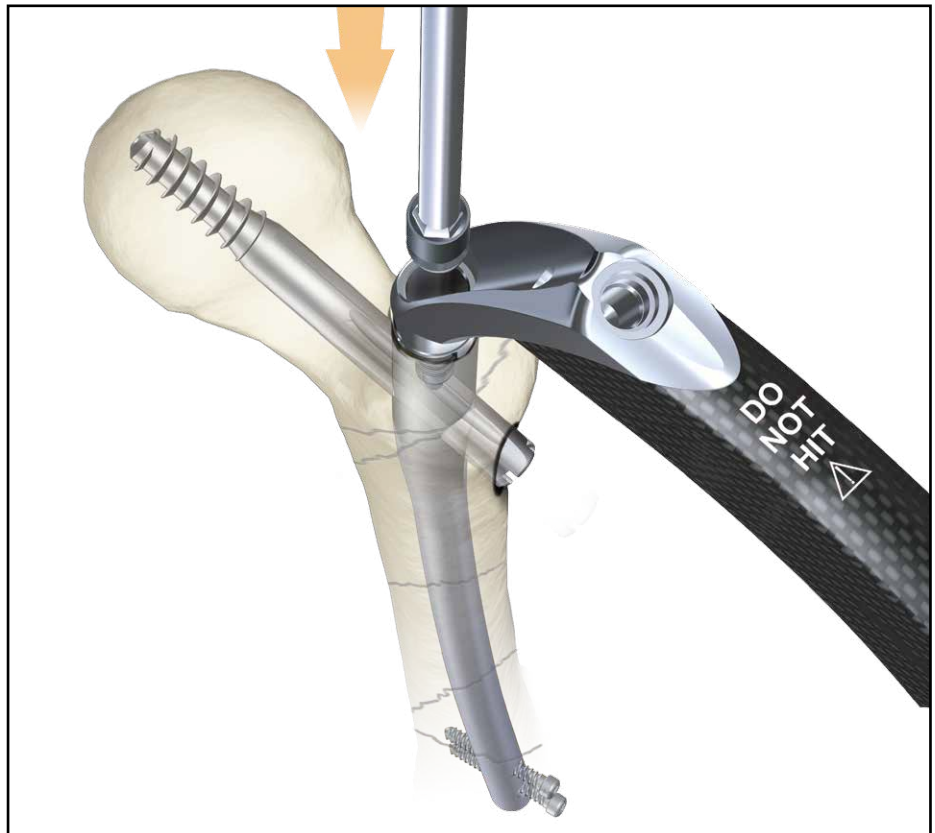It is recommended to use an End Cap to close the proximal part of the nail to prevent bone ingrowth.

Remove the Nail Holding Screw using the Ball Tip Screwdriver, Spreading Screwdriver, Universal Socket Wrench or Strike Plate.

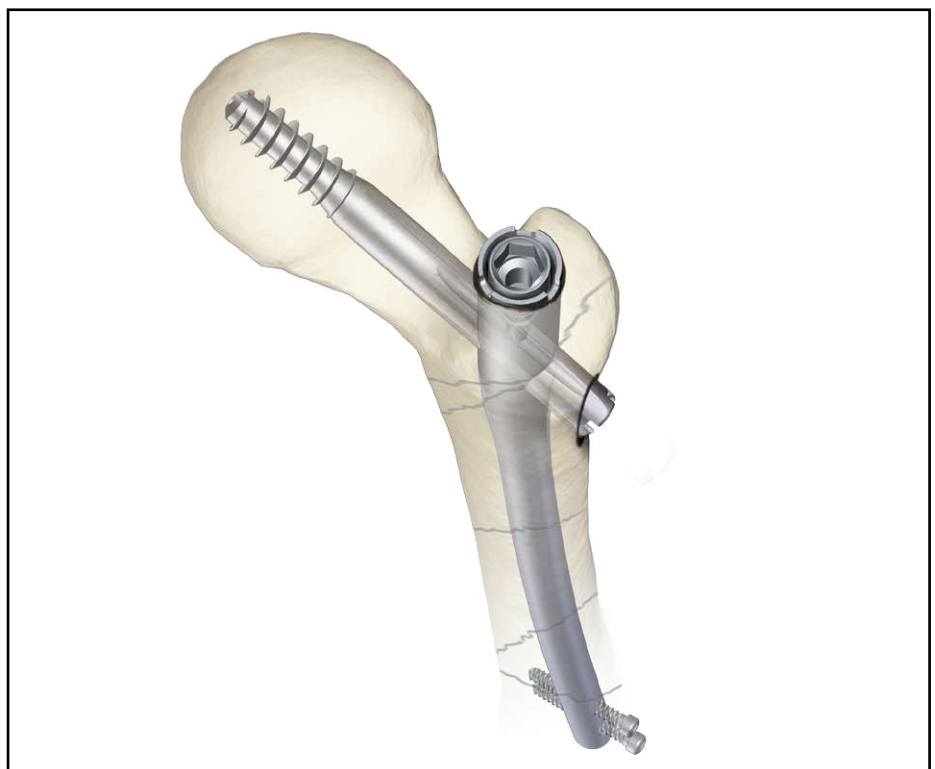Load the End Cap (size 0) to one of the Screwdrivers and pass the assembly through the top of the Targeting Device down into the nail (Fig. 80).

Turn the handle clockwise until it stops mechanically. Remove the Screwdriver and remove the Targeting Device in cranial direction.

Alternatively the End Cap could also be inserted free hand after removal of the Targeting Device.



**Fig. 80**  
End Cap assembly



**Fig. 81**  
Final Nail assembly



# Operative Technique

## Nail Extension End Caps

If the proximal end of the nail is completely sunk in the trochanter, End Caps in size +5mm and +10mm are available and can be assembled to the nail instead of the End Cap size 0, to achieve cortical bone support proximally. The proximal part of the nail will be elongated by 5mm or 10mm.

These elongation End Caps are assembled using the Strike Plate with the self-retaining ring, the Spreading Screwdriver or Ball Tip Screwdriver. This can only be done if the Targeting Device is already removed from the nail.

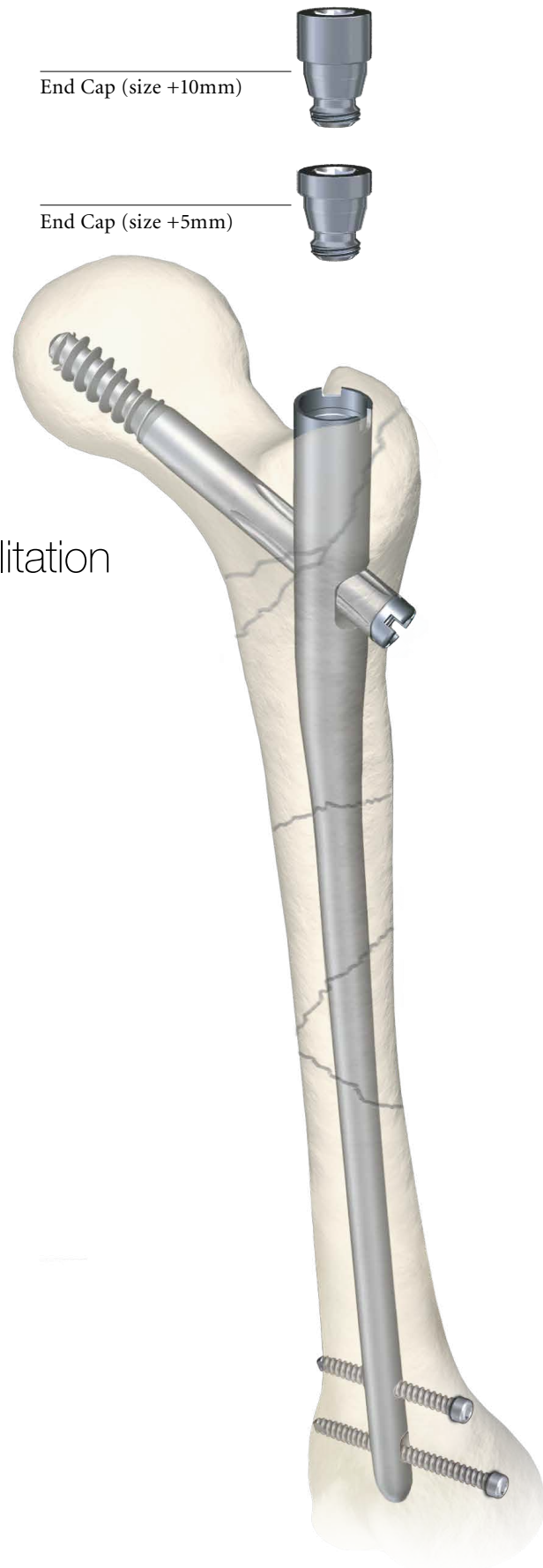
## Post-operative Care and Rehabilitation

Active and passive mobilization of the lower limbs may be started immediately. The injured limb should be kept elevated.

For stable fractures that are locked statically or dynamically, full weight bearing walking may be started immediately.

For unstable fractures with static locking, immediate full weight bearing walking is allowed in fractures with good bone contact.

For fractures with poor bone contact due to comminution, partial weight-bearing walking is allowed for the first 6 to 8 weeks. Full weight bearing walking can be commenced when there is a bridging callus formed as evident on the follow up X-ray.



**Fig. 82**

# Operative Technique

## Extraction of the Gamma3 Implants

Where implant extraction is indicated, please proceed as follows:

### Step I (Fig. 83)

Remove the distal screw using the 3.5mm Screwdriver after making an incision through the old scar.

### Step II (Fig. 84)

Make a small incision through the old scar below the greater trochanter to expose the outer end of the Lag Screw. Remove any bony ingrowth which may be obstructing the outer end or internal thread of the Lag Screw as necessary to enable the Lag Screwdriver to engage fully.

The K-Wire is then introduced via the Lag Screw into the head of the femur. The Lag Screwdriver is passed over the K-Wire, using the Lag Screw Guide Sleeve as a Tissue Protector, and engaged with the distal end of the Lag Screw.

**Check that ingrowth does not obstruct secure engagement of the Lag Screwdriver, otherwise the Lag Screw or Screwdriver may be damaged and extraction will be much more difficult. Tighten the thumbwheel clockwise.**

### Step III (Fig. 85)

An incision is made over the proximal end of the nail, the proximal End Cap if used is removed using the Ball Tip Screwdriver, Spreading Screwdriver or Strike Plate, and the Set Screwdriver is engaged with the Set Screw. The Set Screw is rotated counterclockwise until it is removed.

#### Note:

As the targeting device is not connected to the nail, we recommend using the Straight Set Screwdriver (1320-0210) for better guidance through the soft tissue to get access to the Set Screw.

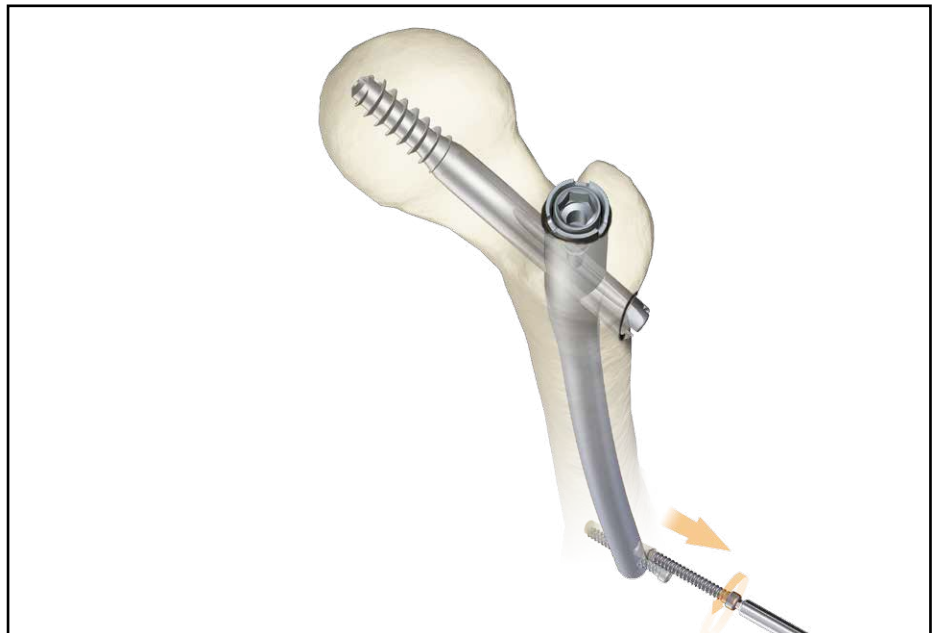

Fig. 83

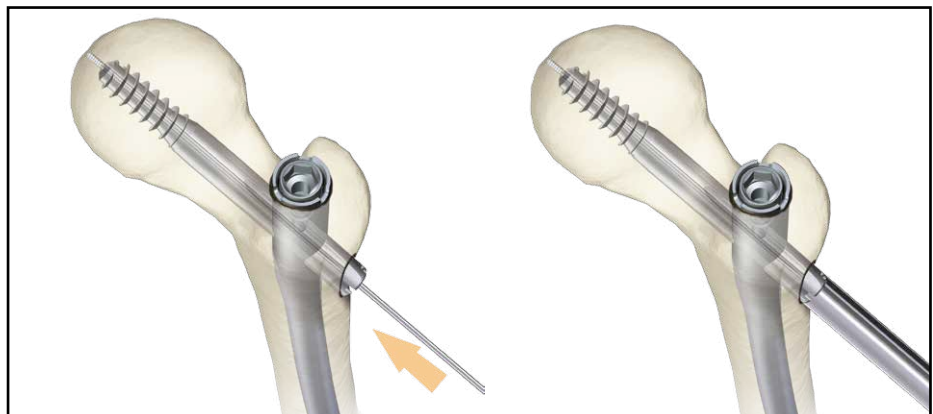


Fig. 84

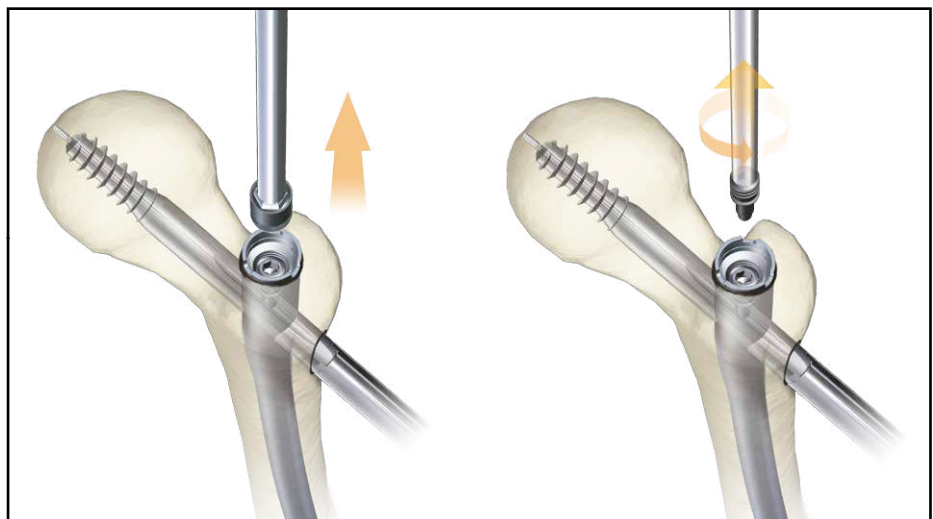


Fig. 85

# Operative Technique

## Step IV (Fig. 86)

The Conical Extraction Rod is then threaded and tightened into the proximal end of the nail. The Lag Screw is extracted by anti clockwise rotation and pulling of the Lag Screwdriver. The K-Wire must then be removed.

### Note:

It is useful to first turn the Lag Screw Screwdriver clockwise slightly to loosen possibly bony ingrowth in the screw threads before turning it counterclockwise.

## Step V (Fig. 87 & 88)

An appropriate sliding hammer assembly is attached to the Extraction Rod and the nail extracted.

### Note:

- It is a useful to turn the Lag Screw Screwdriver clockwise slightly first to loosen the possibly bony ingrowth into the screw threads before turning it counter clockwise.
- As an alternative for implant extraction and even in rare case of broken implants the Stryker Implant Extraction System can be used.

For details, please refer to the “Implant Extraction Set” Guide or ask Stryker Representative for further assistance.

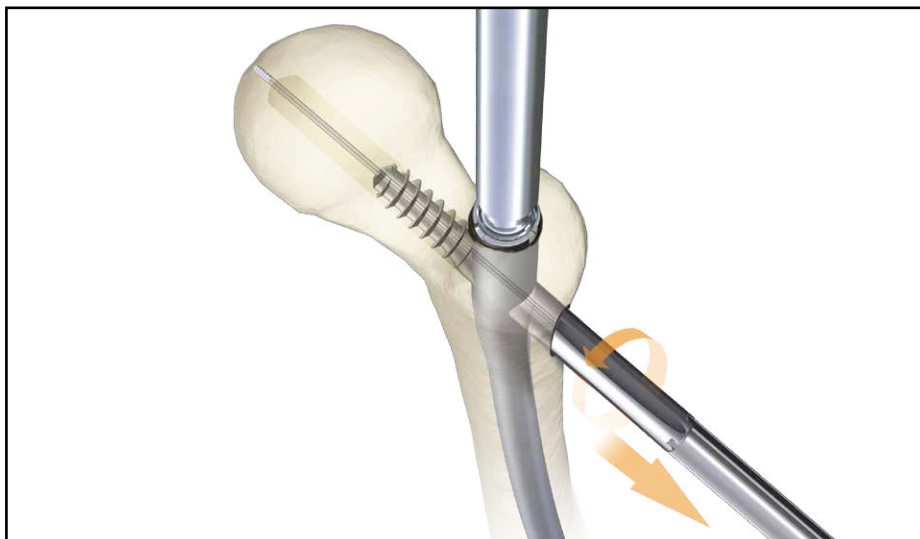


Fig. 86

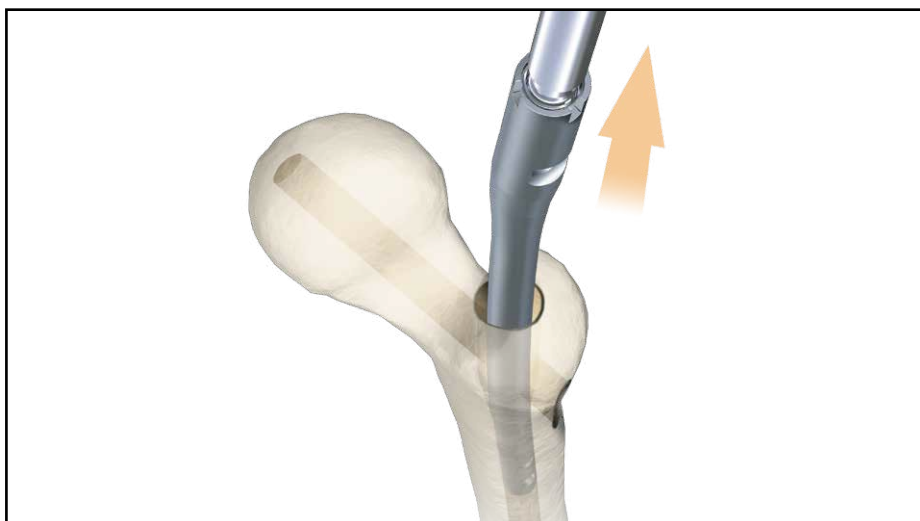


Fig. 87

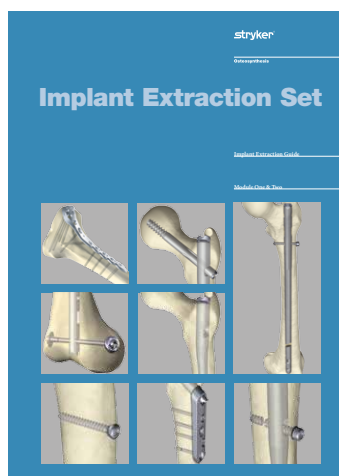


Fig. 88

Implant Extraction Set:

- Quick Reference Guide
- Implant Extraction Guide

# Operative Technique

## Dealing with Special Cases

### Posterior Displacement

In case of a comminuted fracture, there is a tendency of the fracture to become displaced posteriorly, making it difficult to place the K-Wire into the center of the neck and head. This can be solved by lifting the nail insertion Targeting Device (Fig. 89).

Alternatively, an assistant can lift up the greater trochanter manually or with a reduction spoon; or support it with a sandbag. This will maintain the neck and the femur in almost the same axis, facilitating passage of the K-Wire through the center of the neck and head.

The position should then be checked in both the anterior-posterior and lateral views using the image intensifier.

In a case when the proximal fragment is split and making it difficult to place the K-Wire into the center of the femoral neck and head, the Reduction Spatula can be utilized as an option. Enter with the Reduction Spatula from the same incision for the nail entry. Then slide the Reduction Spatula along the surface of the trochanter (Fig. 89a). Gently lift the lever to manipulate the region of the displaced fragment. It is important to continue holding the Reduction Spatula until the Lag Screw insertion is completed (Fig. 89b).

The position should then be checked in both the anterior-posterior and lateral views using the image intensifier.

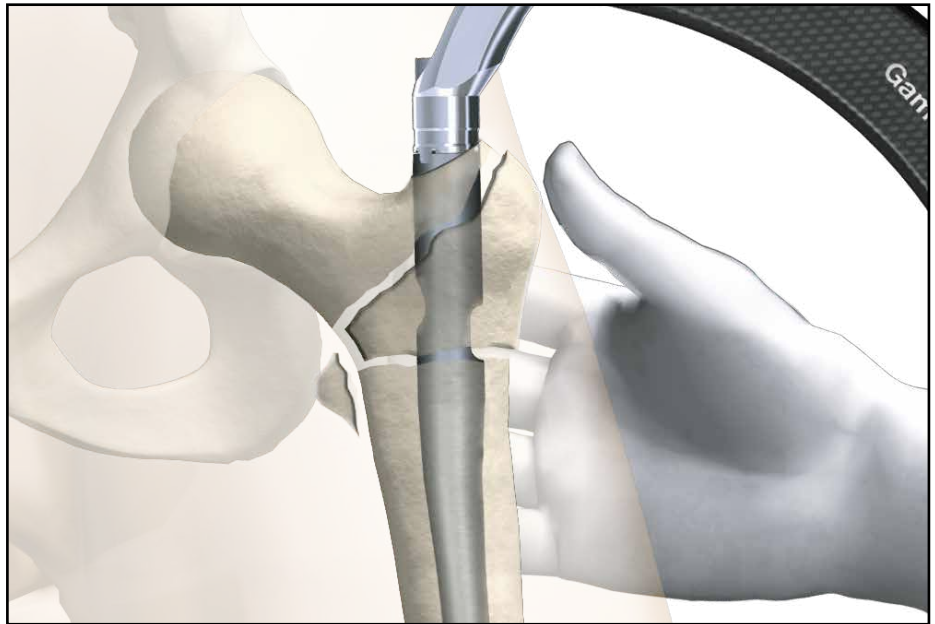


Fig. 89

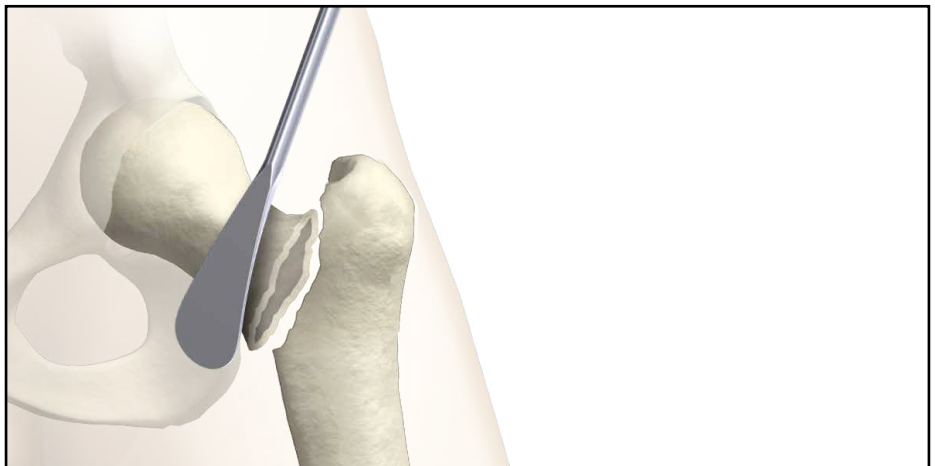


Fig. 89a

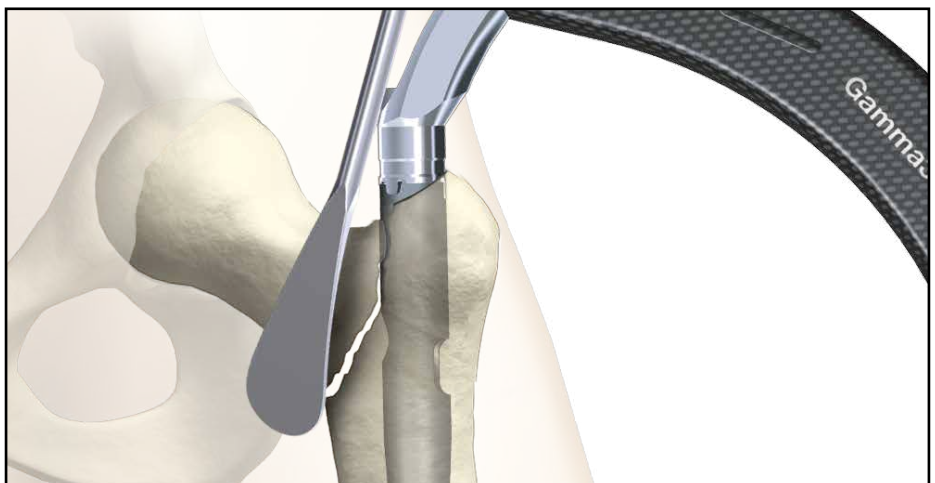


Fig. 89b

# Implants

## Packaging

All implants are packed sterile only.

The Nail and Lag Screw Implant have to be secured using the Set Screw in every surgical operation, without exception (see also page 33).

**The Nail and the Set Screw are therefore supplied together in the same blister pack (see Fig. 90).**

The blister is packed in a white carton and wrapped to protect the contents during transportation and storage.

Only two package sizes are used for all the nails (Fig. 91).

The long nails are packed in a longer box and the short nails in a shorter box.

This facilitates identification in the storage area.

The package carries also the date of sealing and a sterility expiration date.

Gamma3 Set Screw



Gamma3 Long Nail



Long Nail, packaging example



Trochanteric Nail, packaging example

**Fig. 91**

**Fig. 90**

# References

## Publications

Gamma Nail implantations have been performed worldwide since 1988. Extensive clinical experience has been published with the Gamma Locking Nail.

## We recommend the following publications:

- The Gamma Locking Nail, Ten Years Surgical Experience Gahr, R. H.; Leung, K.-S.; Rosenwasser, M. P.; Roth, W. (eds.), Einhorn-Press Verlag, ISBN 3-88756-808-7
- Patients treated with the Long Gamma Nail, R. van Doorn, Bedrijfsnaam: Castellum Drukwerk Vof.

These books contain almost 300 clinical reports available on request.

## Caution:

**The coupling of Elastosil handles contains a mechanism with one or multiple ball bearings. In case of applied axial stress on the Elastosil handle, those components are pressed into the surrounding cylinder resulting in a complete blockage of the device and possible bending.**

**To avoid intra-operative complications and secure long-term functionality, we mandate that Elastosil handles be used only for their intended use.**

**DO NOT HIT any Elastosil handles.**

**Care should be taken to utilize the Cleaning Stylet for intra- and post-operative cleaning of cannulated instruments. Rinsing with saline solution help prevent accumulation of debris.**



# Notes



## Reconstructive

---

Hips  
Knees  
Trauma & Extremities  
Joint Preservation  
Orthobiologics

## Medical & Surgical

---

Power Tools & Surgical Accessories  
Image Guided Navigation  
Endoscopy & Arthroscopy  
Integrated Communications  
Beds, Stretchers & EMS  
Sustainability Solutions

## Neurotechnology & Spine

---

Craniomaxillofacial  
Interventional Spine  
Neurosurgical, Spine & ENT  
Neurovascular  
Spinal Implants

### Manufactured by:

Stryker Trauma GmbH  
Prof.-Küntschers-Straße 1–5  
D - 24232 Schönkirchen  
Germany  
[www.osteosynthesis.stryker.com](http://www.osteosynthesis.stryker.com)

### Distributed by:

Stryker  
325 Corporate Drive  
Mahwah, NJ 07430  
t: 201 831 5000  
[www.stryker.com](http://www.stryker.com)

**This document is intended solely for the use of healthcare professionals.** A surgeon must always rely on his or her own professional clinical judgment when deciding whether to use a particular product when treating a particular patient. Stryker does not dispense medical advice and recommends that surgeons be trained in the use of any particular product before using it in surgery. The information presented in this brochure is intended to demonstrate a Stryker product. Always refer to the package insert, product label and/or user instructions including the instructions for Cleaning and Sterilization (if applicable) before using any Stryker products. Products may not be available in all markets. Product availability is subject to the regulatory or medical practices that govern individual markets. Please contact your Stryker representative if you have questions about the availability of Stryker products in your area.

Stryker Corporation or its divisions or other corporate affiliated entities own, use or have applied for the following trademarks or service marks: Bixcut, Gamma3, Stryker.

All other trademarks are trademarks of their respective owners or holders.  
The products listed above are CE marked.